

Eric Swanson MD

## Purpose

A 2006 survey revealed a high level of frustration among plastic surgeons using a variety of mastopexy and breast reduction techniques.<sup>1</sup> There has been little evidence to support one technique over another. A new breast measurement system and terminology allow comparisons of breast shape before and after surgery, and between inverted-T and vertical techniques, using standardized photos.

## Methods

Patients with “typical” results were selected from a patient database using low z-scores to determine those patients whose measurements were closest to the mean for each treatment group. Patients treated using the inverted-T technique, inferior pedicle, were compared to those treated with the vertical technique and a medial pedicle.<sup>2</sup>

## Results

Measurements demonstrated an increase in breast projection and upper pole projection for vertical mastopexy. The inverted-T mastopexy provided no significant increase in breast projection or upper pole projection. The upper pole contour after vertical mastopexy was linear; after an inverted-T mastopexy, the contour was slightly concave. The inverted-T mastopexy reduced the lower pole distance (length along the lateral curve from maximum breast projection to the posterior breast margin). Both inverted-T and augmentation/mastopexy techniques provided increased breast projection and upper pole projection.

Breast reduction patients demonstrated a loss of breast projection (Fig.1), but there was a slight increase in upper pole projection in the patient treated with the vertical technique. After inverted-T reduction, the upper pole contour was slightly concave, versus parabolic for the vertical reduction. All mastopexy and reduction patients treated with the inverted-T technique had overelevated nipples and shortened lower pole distances.

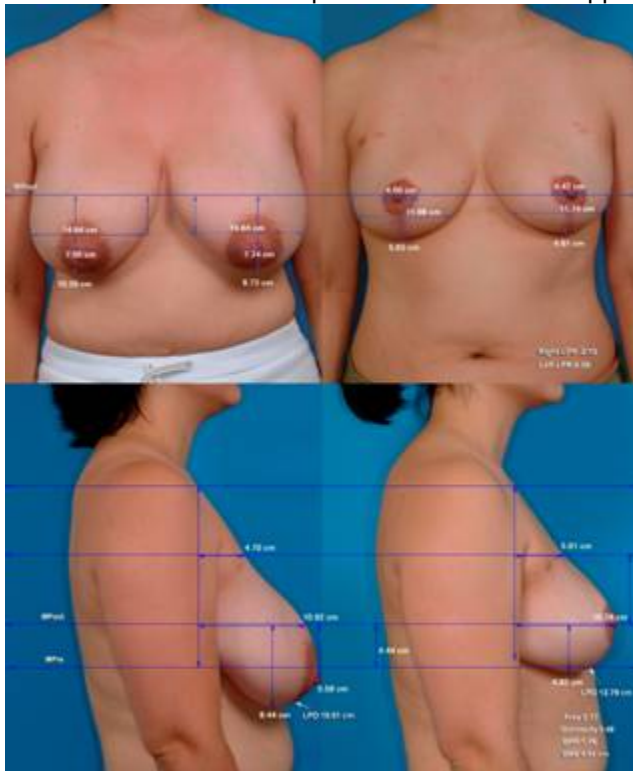


Fig. 1. Vertical breast reduction. (Left) Orientation-matched views of low-z-score 28-year-old patient before and (right) 6 months after vertical breast reduction using a medial pedicle.

## Conclusions

The inverted-T, inferior pedicle technique uses a horizontal resection pattern that results in less breast projection and upper pole projection than the vertical technique and a constricted lower pole, consequences of a horizontal resection pattern (Fig. 2). The vertical design makes use of lower pole tissue to increase projection and provide superior shape.

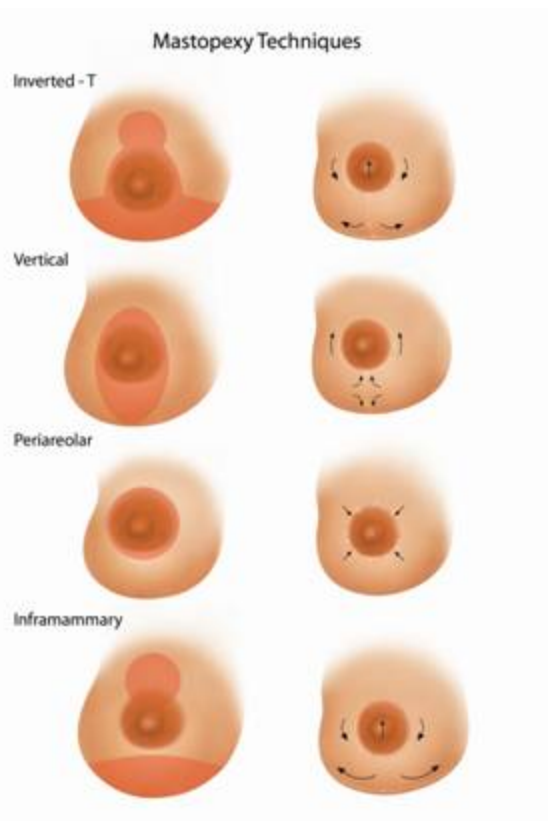


Fig. 2. Resection Patterns.

## References

1. Rohrich RJ, Gosman AA, Brown SA, Reisch J. Mastopexy preferences: a survey of board-certified plastic surgeons. *Plast. Reconstr. Surg.* 2006;118:1631-1638.
2. Hall-Findlay EJ. A simplified vertical reduction mammoplasty: shortening the learning curve. *Plast. Reconstr. Surg.* 1999;104:748-759.