

## **Pectoralis Major Transposition Allows for Immediate Delivery of High Dose Rate Brachytherapy in Previously Irradiated Patients with Recurrent Head and Neck Cancer**

Shwetambara Parakh, MD; Alyssa J. Reiffel, MD; Bhupesh Parashar, MD; David I. Kutler, MD; Jason A. Spector, MD

### **Abstract**

**Background:** Cervical recurrences of previously-irradiated head and neck cancer (H&NC) represent a formidable therapeutic and reconstructive challenge. Brachytherapy (BT) following radical resection increases local control of cervical recurrences of previously-irradiated head and neck cancer (H&NC). However, without bringing vascularized tissue to the operative bed, aggressive local treatment of tissues compromised by previous radiation predisposes patients to significant wound-healing complications. We sought to review our experience with high-dose rate (HDR) BT and pectoralis flap reconstruction for salvage of recurrent H&NC cervical lymphadenopathy.

**Methods:** A retrospective review was performed of all patients who underwent HDR BT for recurrent H&NC at a single institution from 2007 to 2009.

**Results:** Five patients with 6 flaps were included (1 with metachronous bilateral disease). There were 4 primary and 2 secondary recurrences. All patients previously underwent primary cisplatin-based chemotherapy and external beam radiation therapy (RT). Two patients had previous neck dissections. In this series, the surgical approach consisted of radical (n=5) or extended radical (n=1) neck dissection, placement of after-loading HDR catheters (mean=3/site) (Figure 1), and pedicled pectoralis major flap coverage (Figure 2). RT (iridium-192) was initiated within 48h of surgery. Median BT dose was 2000 cGy delivered BID in 200 cGy fractions. All flaps were fully viable at 3months. One patient developed a 1cm superficial dehiscence that resolved with local wound care. One patient who underwent floor-of-mouth resection with concomitant radical neck dissection developed an orocutaneous fistula, which healed following primary repair.

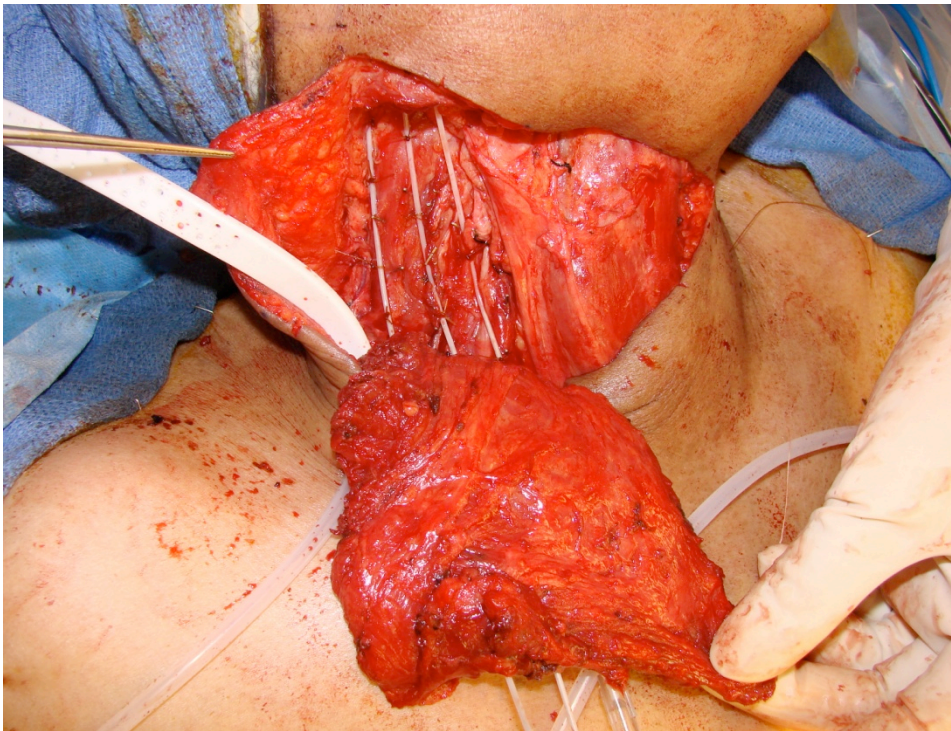


Figure 1: Afterloading brachytherapy catheters in place

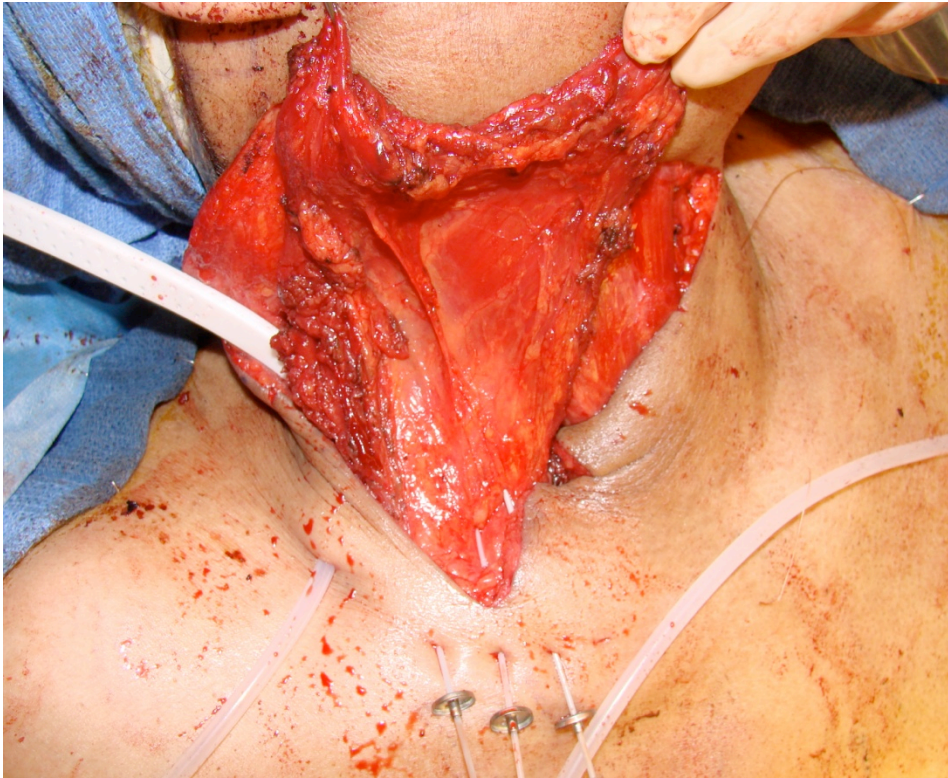


Figure 2: Pedicled pectoralis major muscle flap resurfacing the tumor bed with the afterloading catheters traversing the base of the flap

**Conclusion:** Pectoralis flap reconstruction of oncologic defects in previously-irradiated fields provides reliable coverage of HDR BT catheters and also allows for immediate therapy (within 48h of surgery) without adversely affecting wound healing or flap survival. These data may serve to guide future treatment of complicated H&NC recurrences.

#### References:

1. Schiefke F, Hilderbrandt G, Pohlman S, Heinicke F, Hemprich A, Frerich B. Combination of surgical resection and HDR-brachytherapy in patients with recurrent or advanced head and neck carcinomas. *J craniomaxillofac Surg.* 2008 Jul;36(5):285-92
2. Hepel JT, Syed AM, Puthawala A, Sharma A, Frankel P. Salvage high-dose-rate (HDR) brachytherapy for recurrent head and neck cancer : *Int J Radiat Oncol Biol Phys.* 2005 Aug 1;62(5):1440-50
3. Righi PD, Weisberger EC, Krakovits PR, et al. Wound complications associated with brachytherapy for primary or salvage treatment of head and neck cancer. *Laryngoscope* 1997 Nov;107:1464-1468
4. Moscoso JF, Urken ML, Dalton J, Wesson MF, Biller HF: Simultaneous interstitial radiotherapy with regional or free-flap reconstruction, following salvage surgery of recurrent head and neck carcinoma. Analysis of complications. *Arch Otolaryngol Head Neck Surg.* 1994 Sep;120(9):965-72

#### Disclosure/Financial Support

A portion of this research was funded by a Ruth L. Kirschstein National Research Service Award (Kirschstein-NRSA) Institutional Research Training Grant (T32 HL083824 05 to Dr. Alyssa J. Reiffel).

None of the authors have any commercial associations or financial disclosures that might pose or create a conflict of interest with information presented in this manuscript.