

Dynamic Definition Lipoabdominoplasty

Authors: Alfredo E. Hoyos, MD, Mauricio E. Perez, MD.

BACKGROUND: Lipectomy was first mentioned in 1899 and several technique innovations have been documented since then as the perfect procedure to provide skin removal in specific cases^{1,2}. Liposuction is one of the new adjuvant procedures for abdominoplasty [1]. Although results became reproducible and aesthetically pleasant, stigmata of lipectomy like the scarred navel and the "stretched" look of the flap skin are relevant to produce unnatural results.

OBJECTIVE: the author describes Dynamic Definition Full Lipoabdominoplasty as a new reproducible technique, with a three-dimensional approach, based on High Definition liposculpture premises³, to enhance the areas of liposuction and take away the visual stigmata of the procedure.

MATERIALS AND METHODS: From January 2005 to January 2012, a total of 147 consecutive procedures were performed. Ages ranged from 24 to 67 (\bar{x} =42). Liposculpture was the first phase by dynamic (360-degree and multilayered) definition of the desired areas in an anatomical fashion. Also selective fat grafting in the gluteal area was performed. Lipectomy (second phase) was performed by flap tunneling technique and plication of the rectus abdominis m. Flap advance and closure were carefully and anatomically achieved. Follow up was accomplished within 24 and 48 hours, one, three, six and twelve months after surgery. Umbilicoplasty was selectively done after 8 to 60 days after the procedure in most cases.

RESULTS: Most patients were satisfied with the results (93%). Major complication (1) was reported as wound border suffer, solved with early carboxiterapy, no secondary surgery was needed. Minor complications as bruising and seroma were highly reported (60%), most of them occurred after drain removal. No flap necrosis was reported in our series of cases.

CONCLUSION: Dynamic Definition Tummy tuck is a reproducible technique in abdominoplasty, aesthetically pleasant results can be achieved while an athletic contour gives a more natural result, successfully taking away the "lipectomy" appearance.

LEVEL OF EVIDENCE: Level IV: Case report and descriptive study.

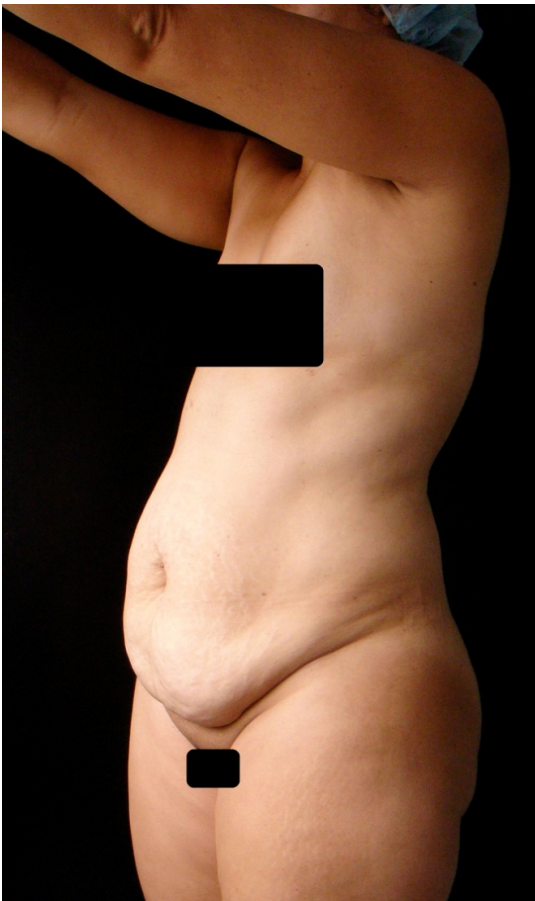


Figure 1: A 44-year old woman. Preoperative photo. Notice the excess fat and the redundant skin in the abdomen.

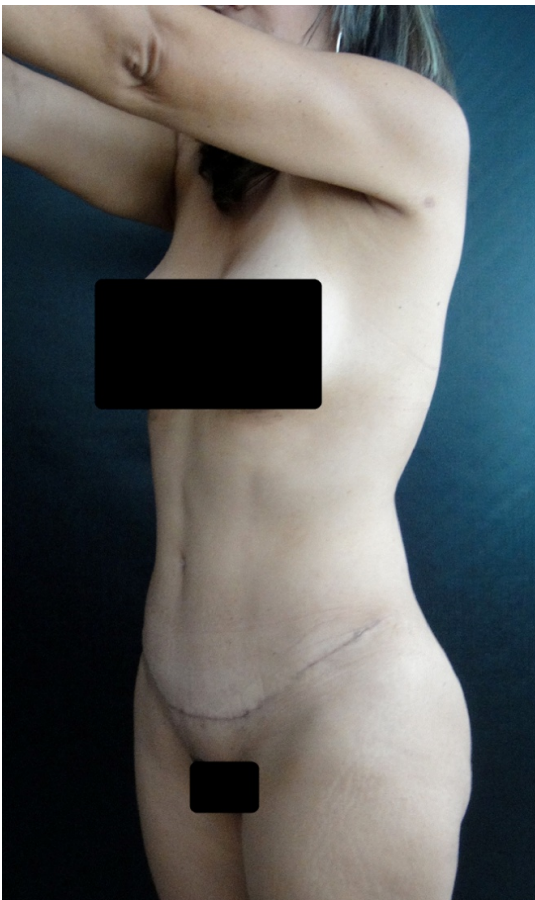


Figure 2: A 44-year old woman. Postoperative photo. Notice the new athletic and slimmer appearance. The normal women underwear can dissimulate the scar.

Disclosures

The authors declare that they have no conflict of interest.

References

- (1) Avelar JM, MD. Abdominoplasty Combined with Lipoplasty Without Panniculus Undermining: Abdominolipoplasty—a Safe Technique, *Clin Plastic Surg* 33 (2006) 79–90
- (2) M. A. Shiffman, S. Mirrafati (Eds.) *Aesthetic Surgery of the Abdominal Wall*, Springer-Verlag Berlin Heidelberg 2005
- (3) Hoyos AE, Millard JA. Vaser-assisted High definition Lipoplasty. *Aesthetic Surg J.* 2007;27:594-604