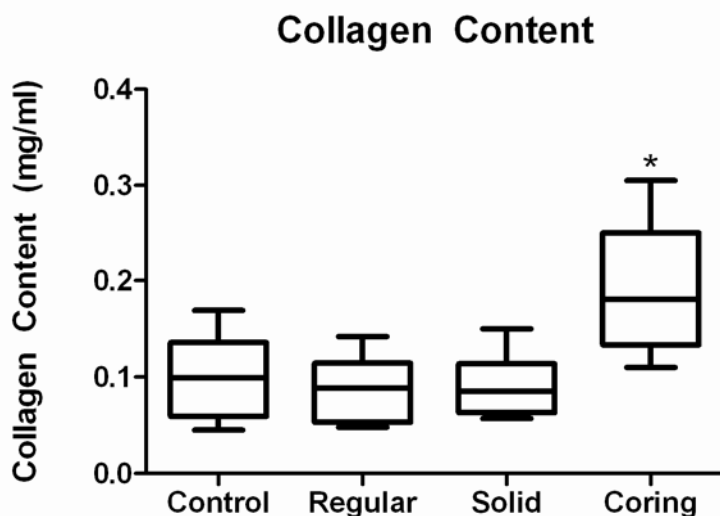


Justin R. Fernandes, MD, Juan C. Samayoa, MD, G. Felix Broelsch, MD, Michael C. McCormack, MBA, Alexa M. Nicholls, BS, Mark A. Randolph, MAS, Martin C. Mihm, MD, William G. Austen, Jr., MD

**Background:** As the population ages, there is an increasing demand for safe and effective skin rejuvenation. The most commonly performed skin rejuvenation procedure, laser resurfacing, is associated with adverse events and significant expense.(1-4) We have developed a novel device that utilizes micro-coring needles, which remove tissue in a fractional pattern, and avoid the side effects of laser therapy. We compare the efficacy of these needles to standard needles, in a pig model.

**Methods:** One swine was treated with three needle types: standard hypodermic, solid hypodermic, and our novel coring needles. Thirty-two 1 x 1 inch sites per flank, received either 20% or 40% treatment coverage. Photographs and punch biopsies were performed at day 0, 7, 28, 56 and 84. Biopsies were evaluated for histology and collagen content.

**Results:** All treatment sites healed quickly, with no evidence of scarring or infection. Coring sites were easily identified and contained increased fibroblast activity and newly synthesized collagen. At one month, we found the papillary dermis and epidermis of the coring sites to be up to 196% thicker, compared to controls ( $p<0.001$ ). The coring sites had enhanced undulating rete ridges—consistent with regeneration. At three months we observed a pronounced increase in collagen fibers and newly organized and augmented elastic fibers. ELISA confirmed an 89% increase in collagen content in these coring sites ( $p<0.001$ ) (Figure 1).



**Figure 1.** Total Collagen Content at 3 months expressed as means of control (untreated), regular (hypodermic), solid and coring needles. Error bar represent standard deviation. (\*) indicates  $p<0.001$ .

**Conclusions:** This novel approach was found to effectively induce the microscopic and biologic endpoints of skin rejuvenation. This may provide a new modality for the safe and cost-effective treatment of age related rhytides, skin laxity, photo damage, scarring and striae.

### References

1. Bernstein LJ, Kauvar AN, Grossman MC, et al: The short- and long-term side effects of carbon dioxide laser resurfacing. *Dermatol Surg*; 23(7):519-25; 1997.
2. Grema H, Greve B, Raulin C: Facial rhytides--subsurfacing or resurfacing? A review; *Lasers Surg Med*; 32(5):405-12; 2003.
3. Manstein D, Herron GS, Sink RK, et al: Fractional photothermolysis: a new concept for cutaneous remodeling using microscopic patterns of thermal injury; *Lasers Surg Med*; 34(5):426-38; 2004.
4. Fife DJ, Fitzpatrick RE, Zachary CB. Complications of fractional CO2 laser resurfacing: four cases. *Lasers Surg Med*; 41(3):179-84; 2009.

### Disclosure/Financial Support

This work was supported by departmental funds.

None of the authors has a financial interest in any of the products, devices, or drugs mentioned in this manuscript.