

## Pertinent Midface Anatomy & Analysis for Volumizing Procedures

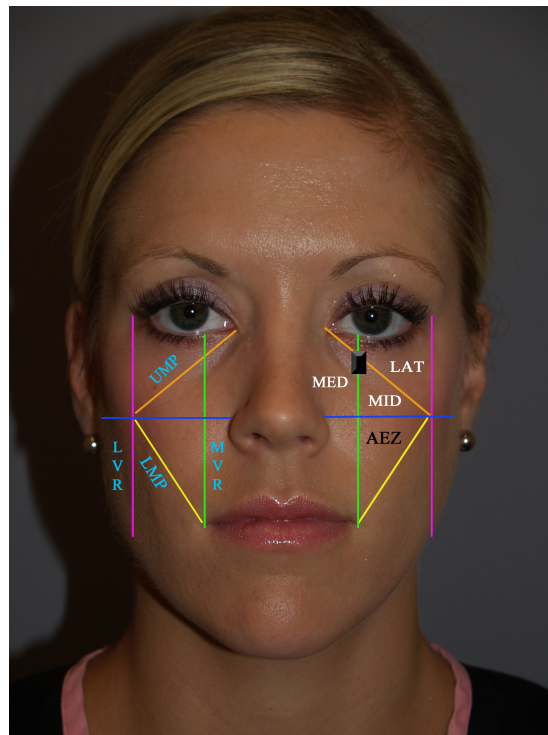
Christopher C. Surek DO; Javier Beut MD; Robert Stephens PhD; Jerome Lamb MD; Glenn Jelks MD

### Abstract

**Purpose:** Great interest has been placed on understanding the layered and spatial relationships existing in the midface.<sup>[1-5]</sup> We seek to construct an anatomically inspired midfacial analysis facilitating safe, accurate and dynamic non-surgical rejuvenation. Emphasis is placed on determining injection target areas and adverse event zones.

**Methods:** Ten hemifacial fresh cadavers were dissected in a layered fashion. Dimensional measurements between the midfacial fat compartments, pre-zygomatic space, mimetic muscles and neurovascular bundles were used to develop a topographic analysis for clinical injections.

**Results:** A longitudinal line from the base of the alar crease to the medial edge of the Levator Anguli Oris muscle (LAO) [1.9 cm], lateral edge of the LAO [2.6 cm] and Zygomaticus Major muscle [4.6 cm] partitions the cheek into two aesthetic regions. A six-step facial analysis outlines three target zones, two adverse event zones and triangulates the point of maximum cheek projection. The *lower adverse event zone* yields an anatomical explanation to inadvertent jowling during anterior cheek injection. The *upper adverse event zone* localizes the palpebral branch of the infraorbital artery. The medial malar target area isolates quadrants for anterior cheek projection and tear trough effacement. The middle malar target area addresses lid-cheek blending and superficial compartment turgor. The lateral malar target area highlights lateral cheek projection and locates the pre-zygomatic space (Figure 1).



**FIGURE 1:** Topographic facial analysis markings. Lateral Vertical Reference (pink), Medial Vertical Reference (green), Upper Malar Partition (orange), Lower Malar Partition (yellow). Upper Malar Adverse Event Zone (black square), Lower Malar Adverse Event Zone (AEZ). Medial Malar Target Area (MED), Middle Malar Target Area (MID), Lateral Malar Target Area (LAT).

**Conclusions:** This stepwise analysis illustrates target areas and adverse event zones to achieve midfacial support, contour and profile in the repose position while simultaneously molding a natural shape during animation. This reproducible method can be utilized both procedurally and in record keeping for midface volumization procedures.

**References:**

1. Stuzin J, Baker T, Gordon H. The relationship of the superficial and deep facial fascias: Relevance to Rhythidectomy and Aging. *Plastic and Reconstructive Surgery*. 89: 441, 1992.
2. Mendelson B, Muzaffar A, Adams W. Surgical anatomy of the midcheek and malar mounds. *Plastic and Reconstructive Surgery*. 2002; 110: 885-896, discussion 897-911
3. Rohrich R, Pessa J. The Fat Compartments of the Face: Anatomy and Clinical Implications for Cosmetic Surgery. *Plastic and Reconstructive Surgery*. June 2007, 119:7 p 2219-2227.
4. Rohrich R, Pessa J, Rustow B. The Youthful Cheek and the Deep Medial Fat Compartment. *Plastic and Reconstructive Surgery*. June 2008, 121:6 p 2107-2112.
5. Gierloff M, Stohring C, Buder T, Gassling V, Acil Y, Wiltfang J. Aging Changes of the Midfacial Fat Compartments: A Computed Tomographic Study. *Plastic and Reconstructive Surgery*. 2012; 129: 1. 263-273

**Disclosure/Financial Support**

None of the authors have financial interests to disclose related to this research