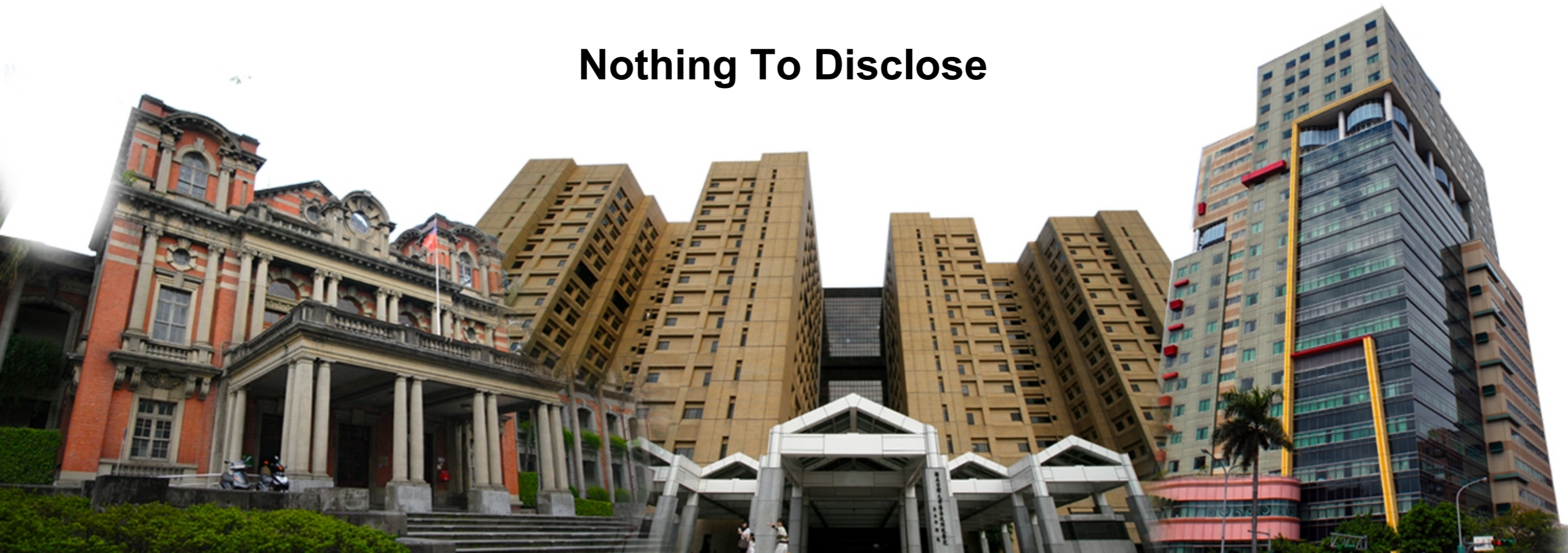

Innovation : Lengthened Penile Skin-Urethral-Scrotal Flap for Neovaginoplasty of Male Transsexuals

Po-Cheng Huang, M.D. Shyeu-Yih Horng, M.D.

The Division of Plastic and Reconstructive Surgery,
Department of Surgery,
National Taiwan University Hospital, Hsin-Chu Branch

Nothing To Disclose





Objective

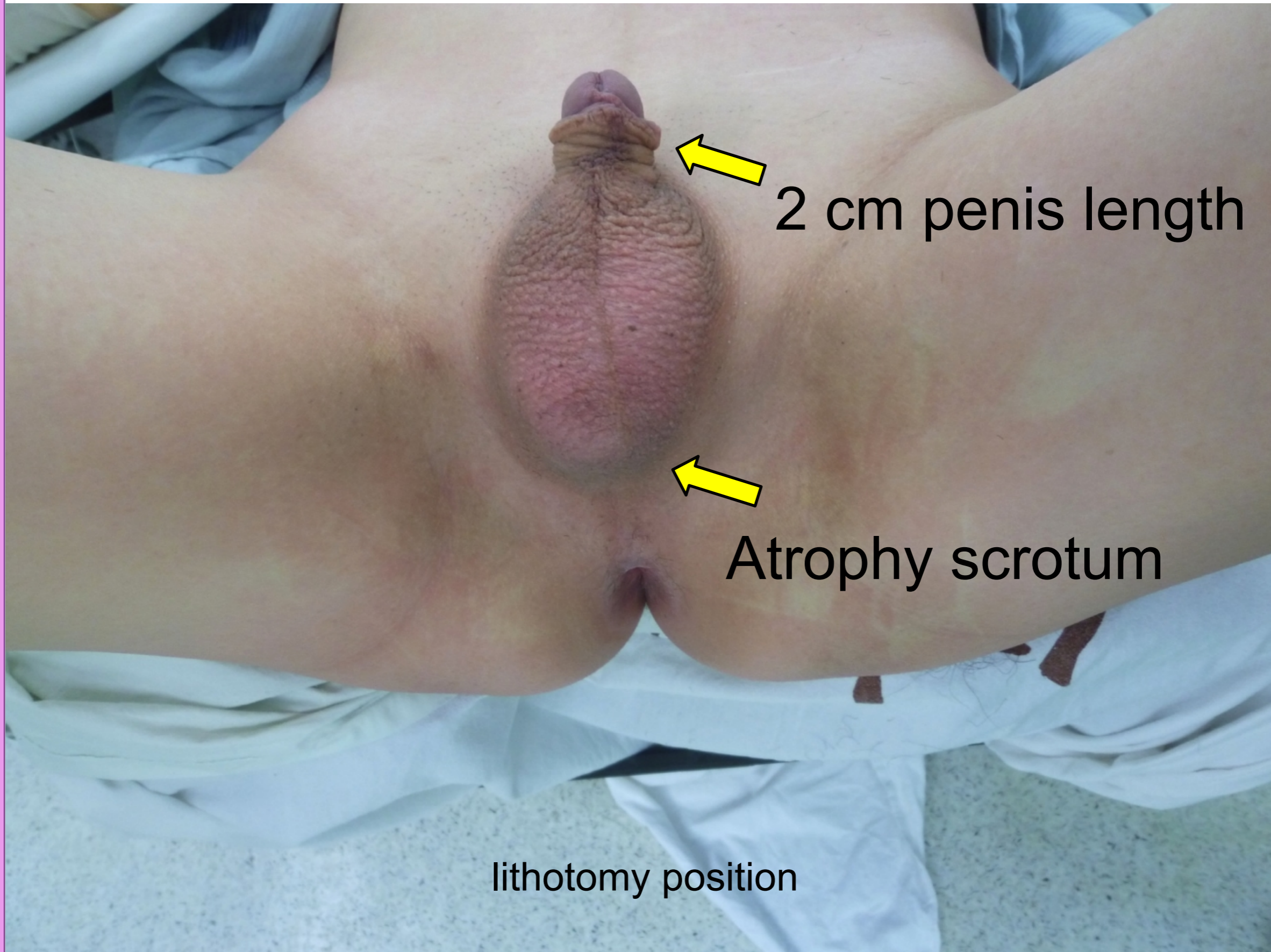
- ◆ Neovaginoplasty is one part surgery of sex assignment surgery (SAS).
- ◆ Eastern used hormone therapy made shorten and smaller external genital organ.
- ◆ We created a new flap for neovaginoplasty of male transsexuals to resolve and make the ideal vaginal length.



Material and Method

- 28 y/o male denied any systemic disease
- sexual identity problem since senior high school
- Psychiatric OPD since 2009
- Hormone therapy since 2011-08
- Sex reassignment surgery (SRS) 2012-12

Pre-Operation

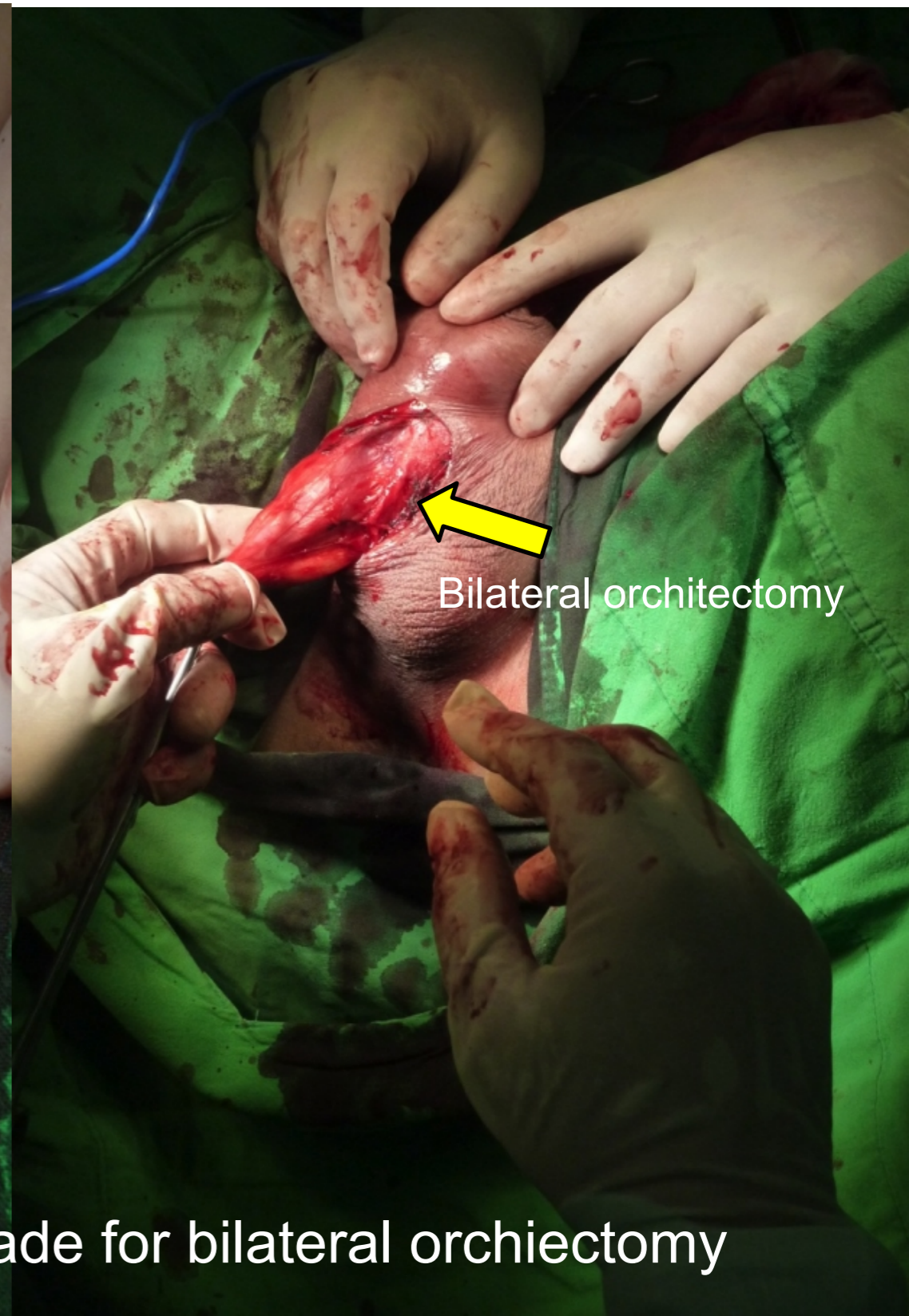
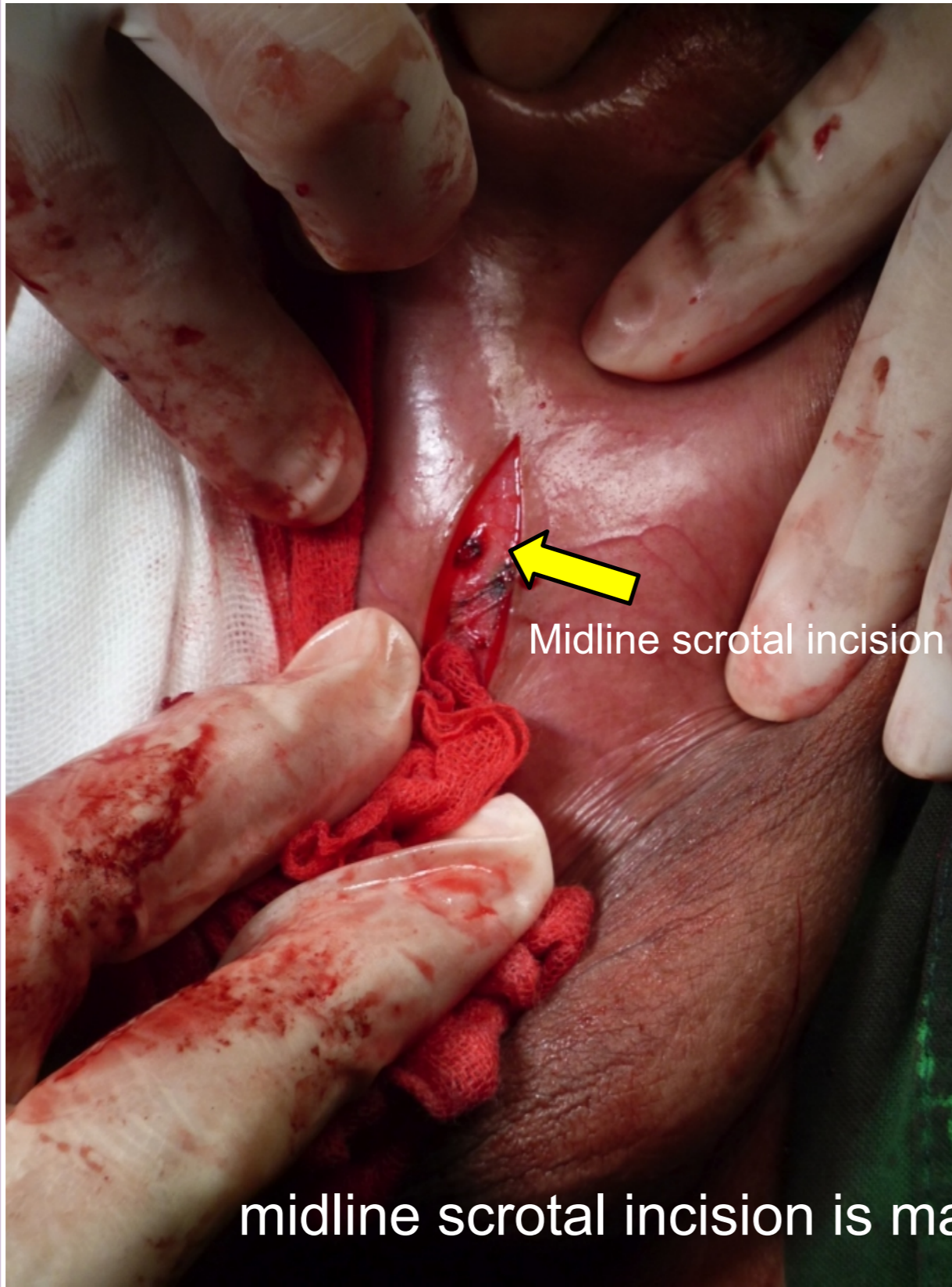

2 cm penis length

Atrophy scrotum

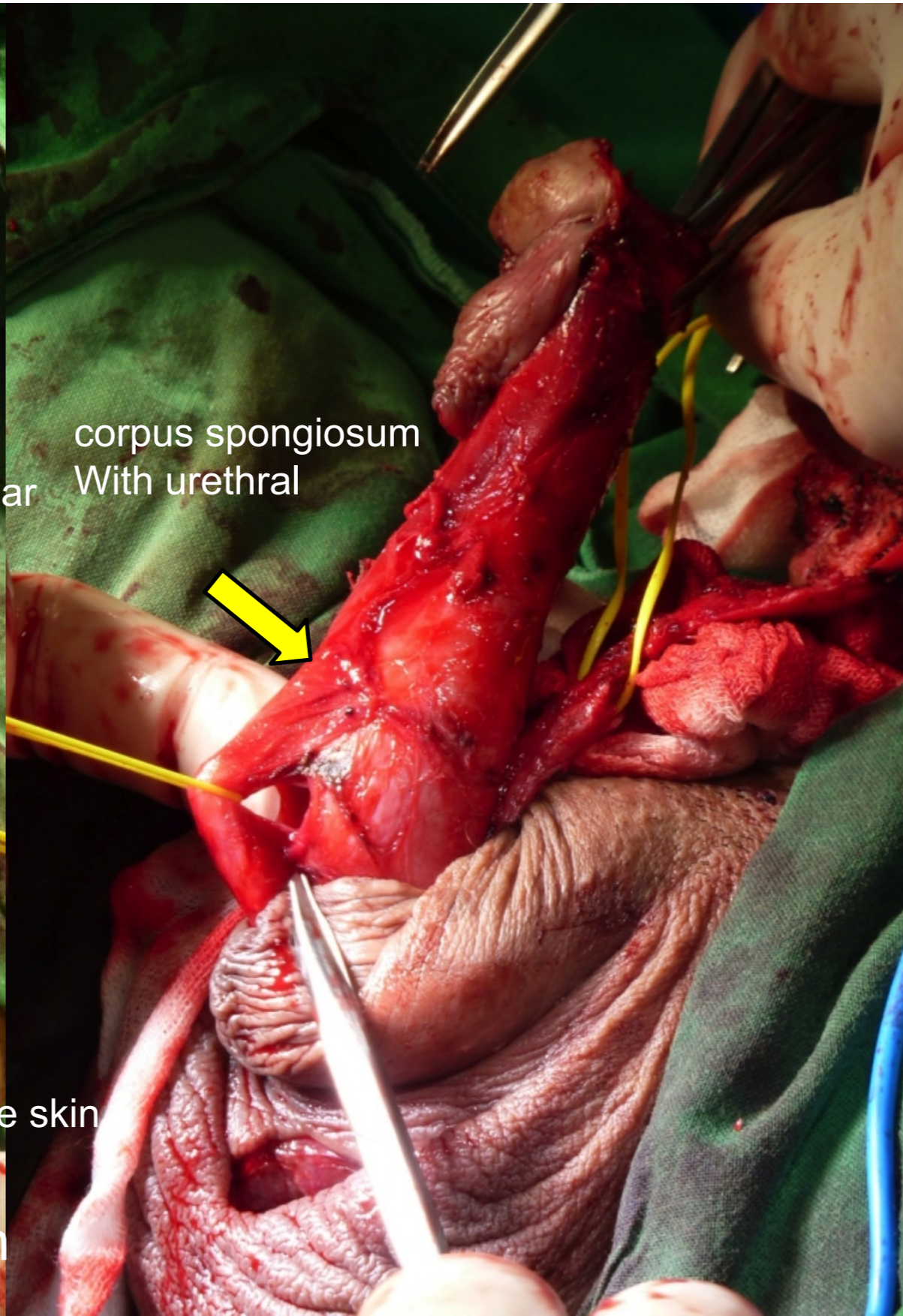
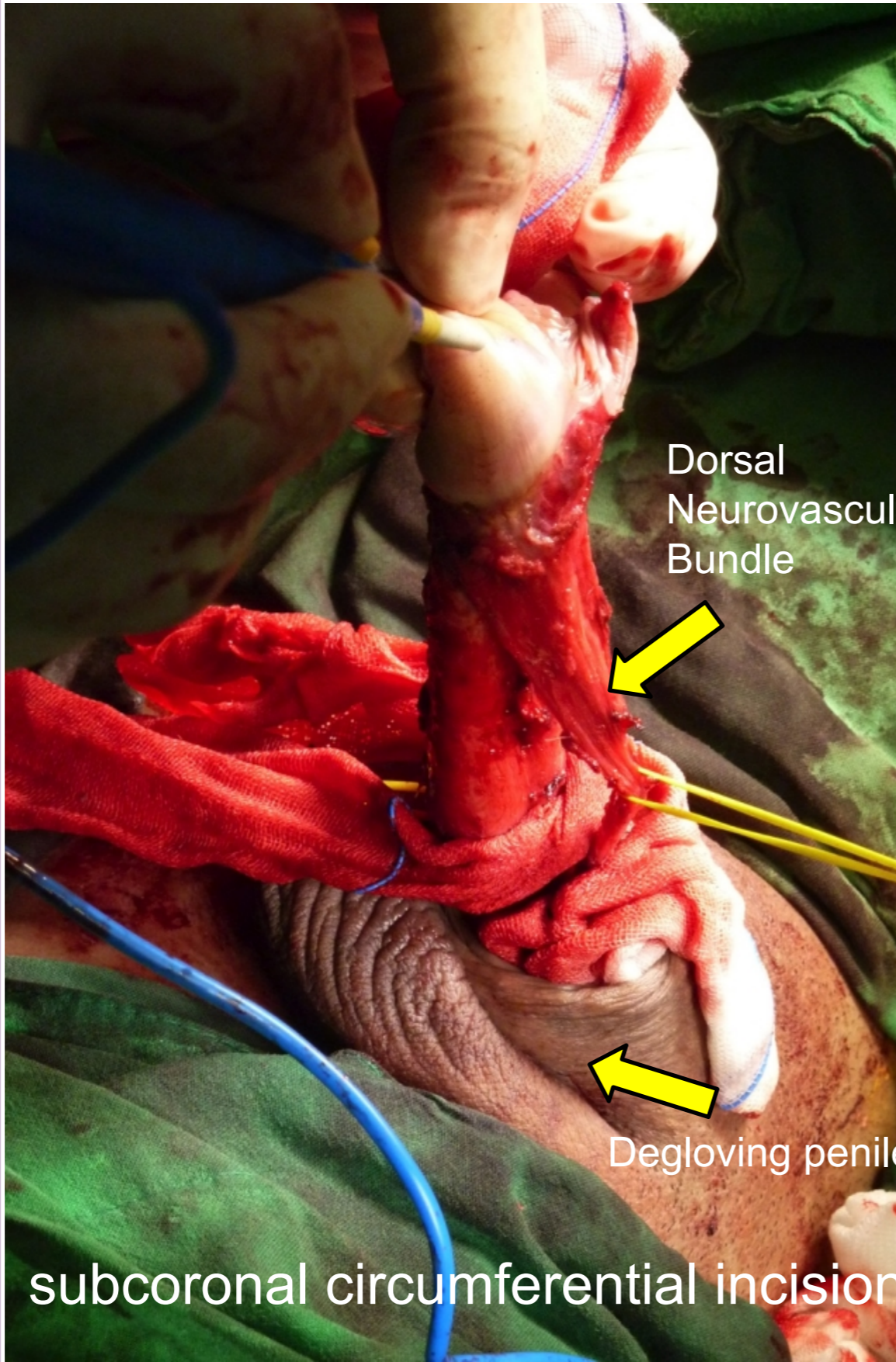
lithotomy position

orchiectomy



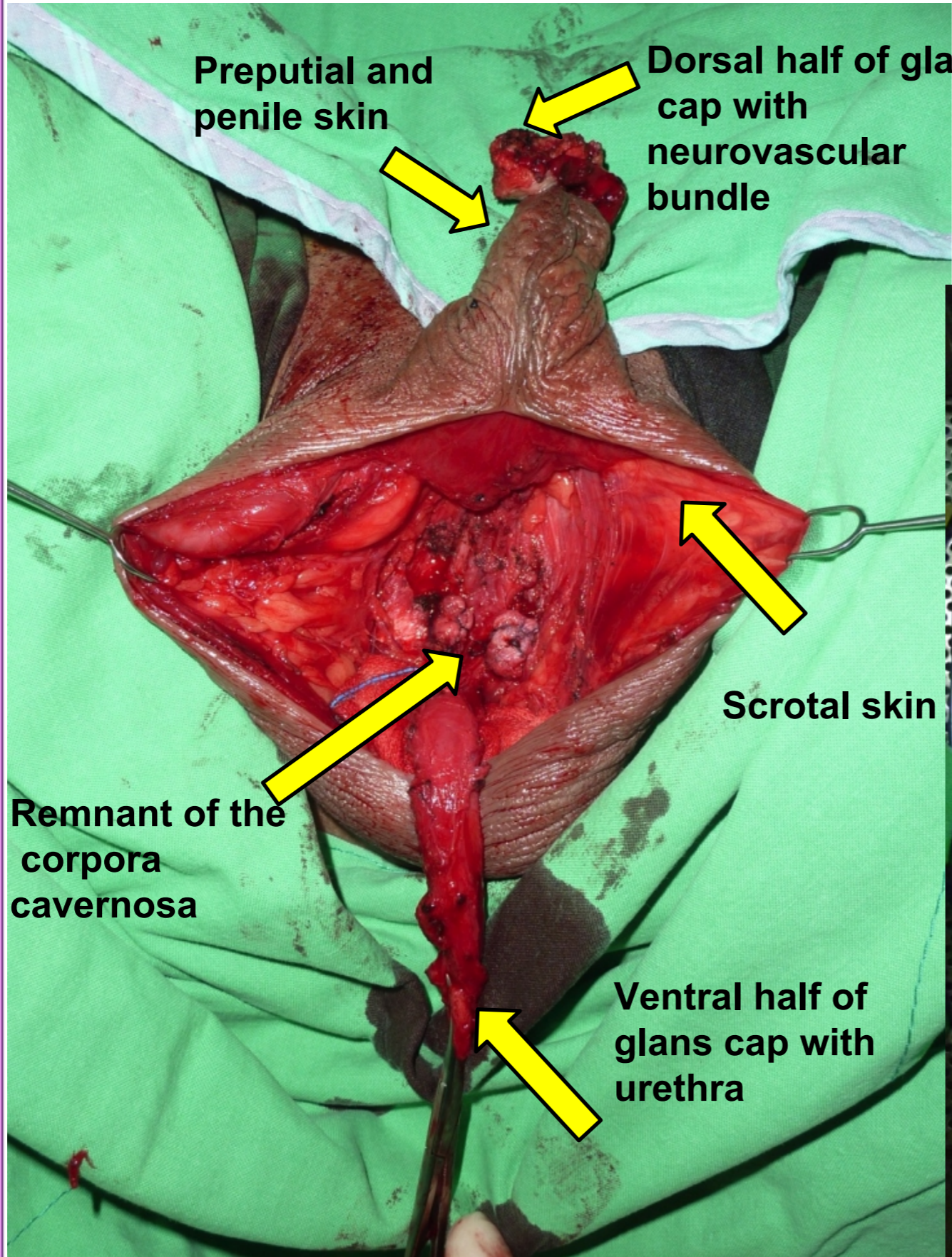
midline scrotal incision is made for bilateral orchiectomy

Penile Disassembly

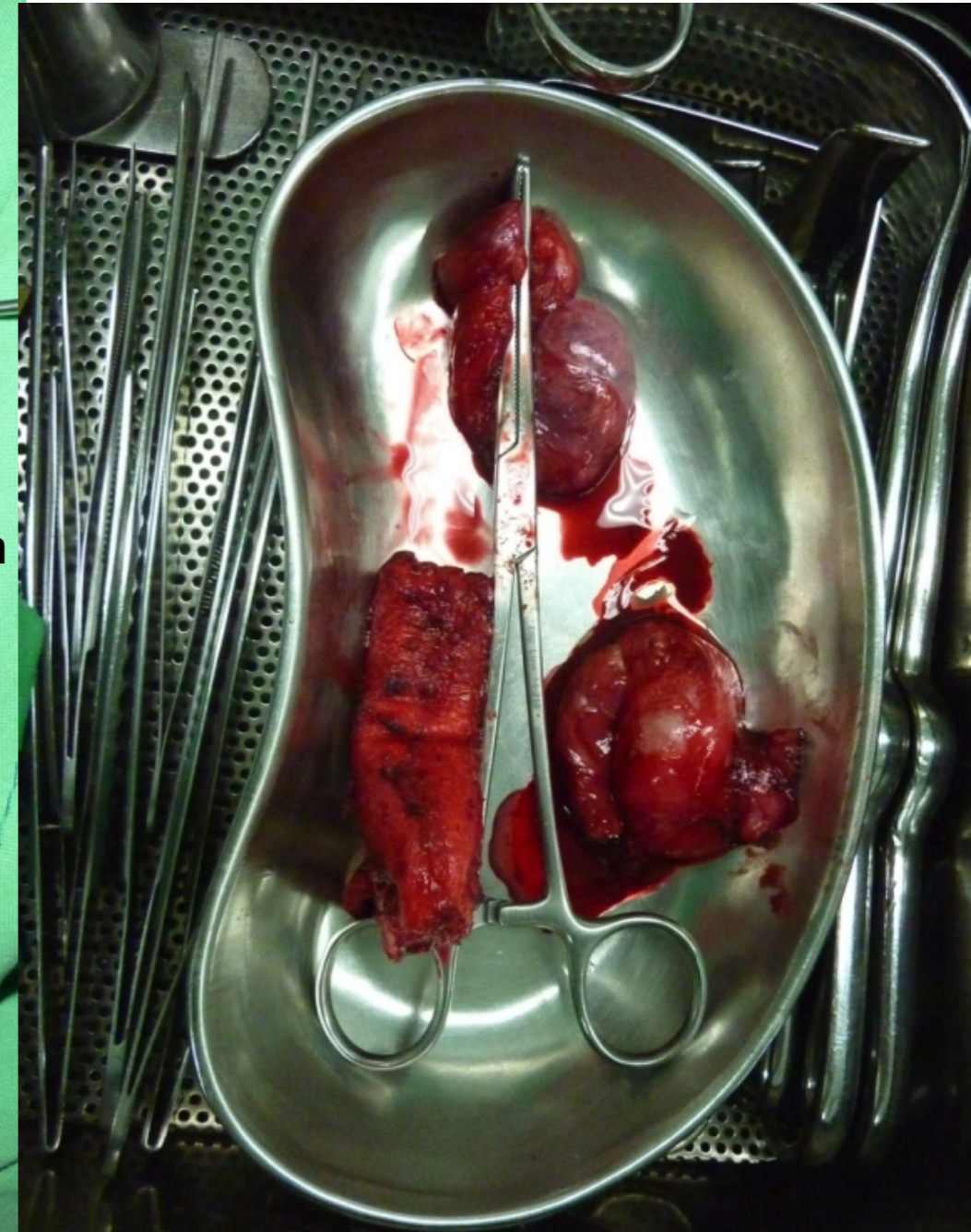


subcoronal circumferential incision

Complete Disassembly

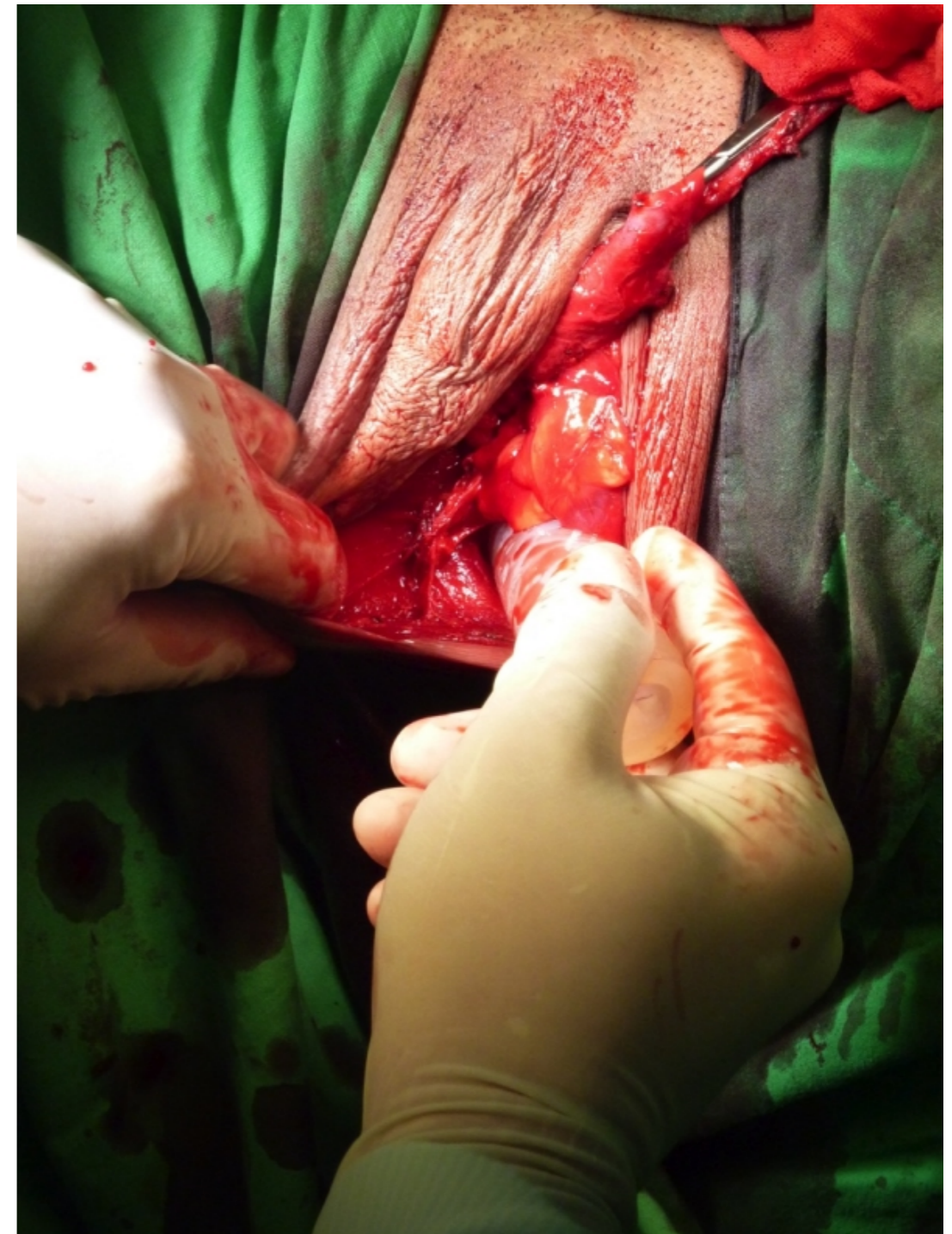
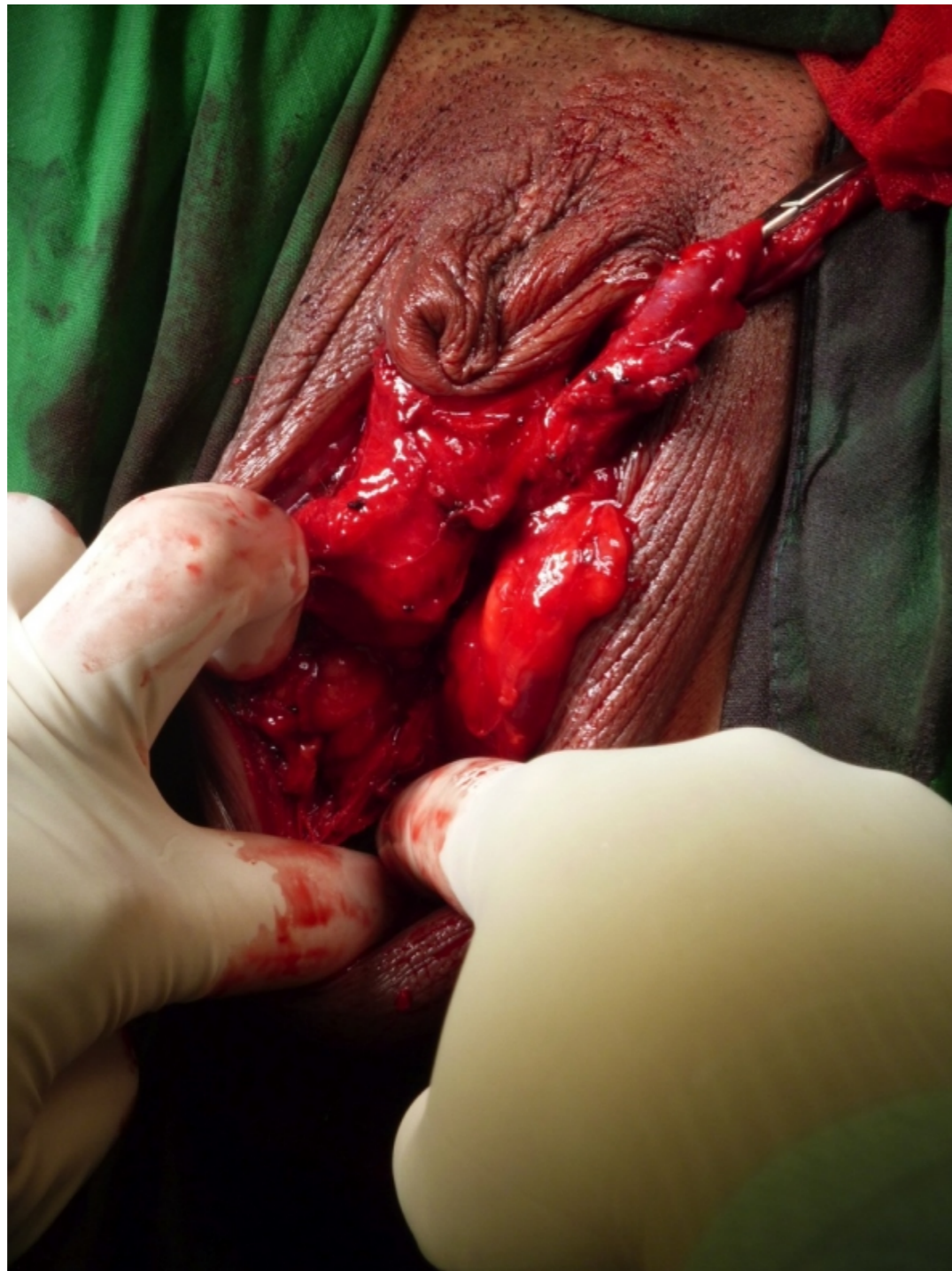
Penectomy and
Orchitectomy



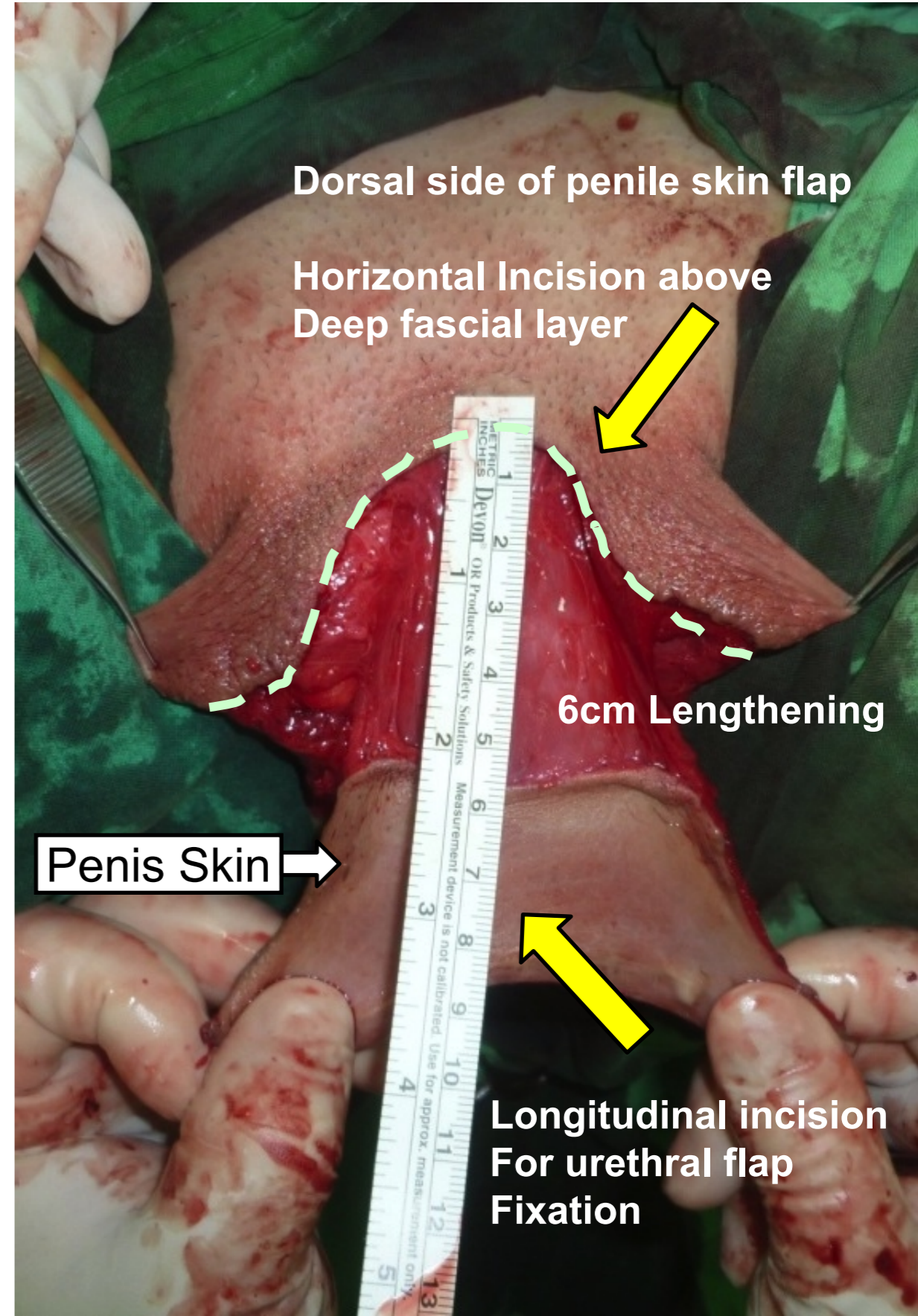
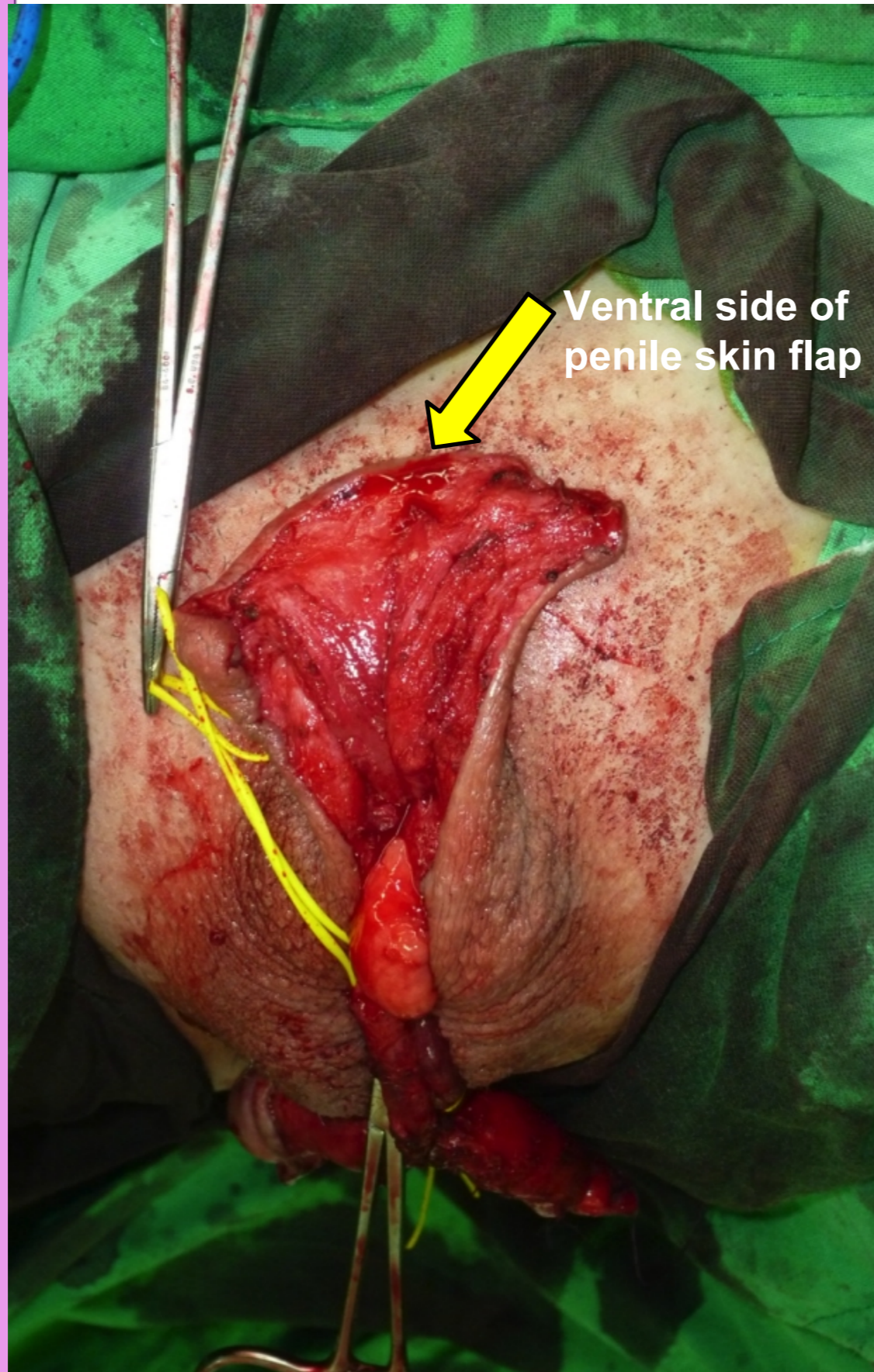


Create Neovagina Tunnel

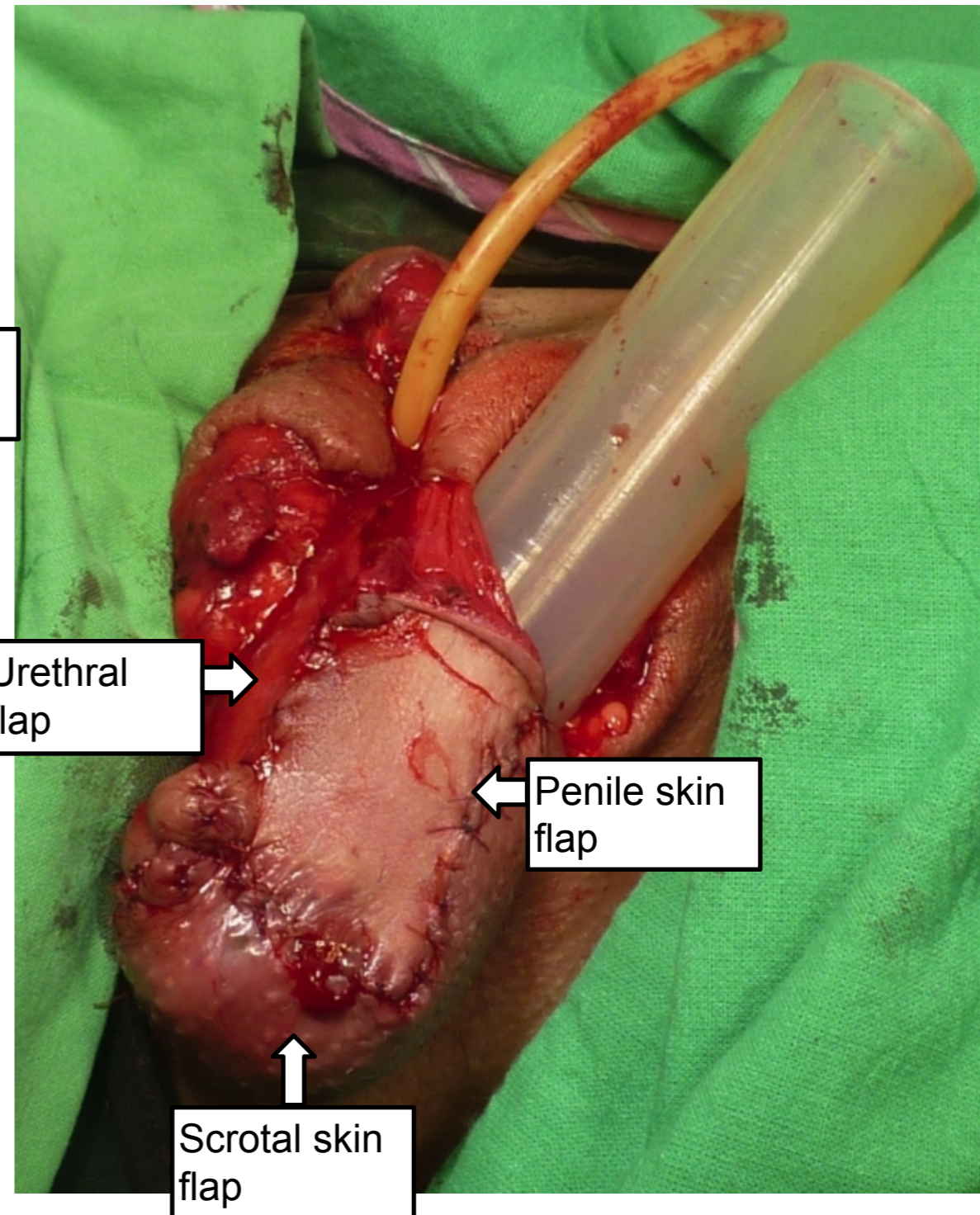
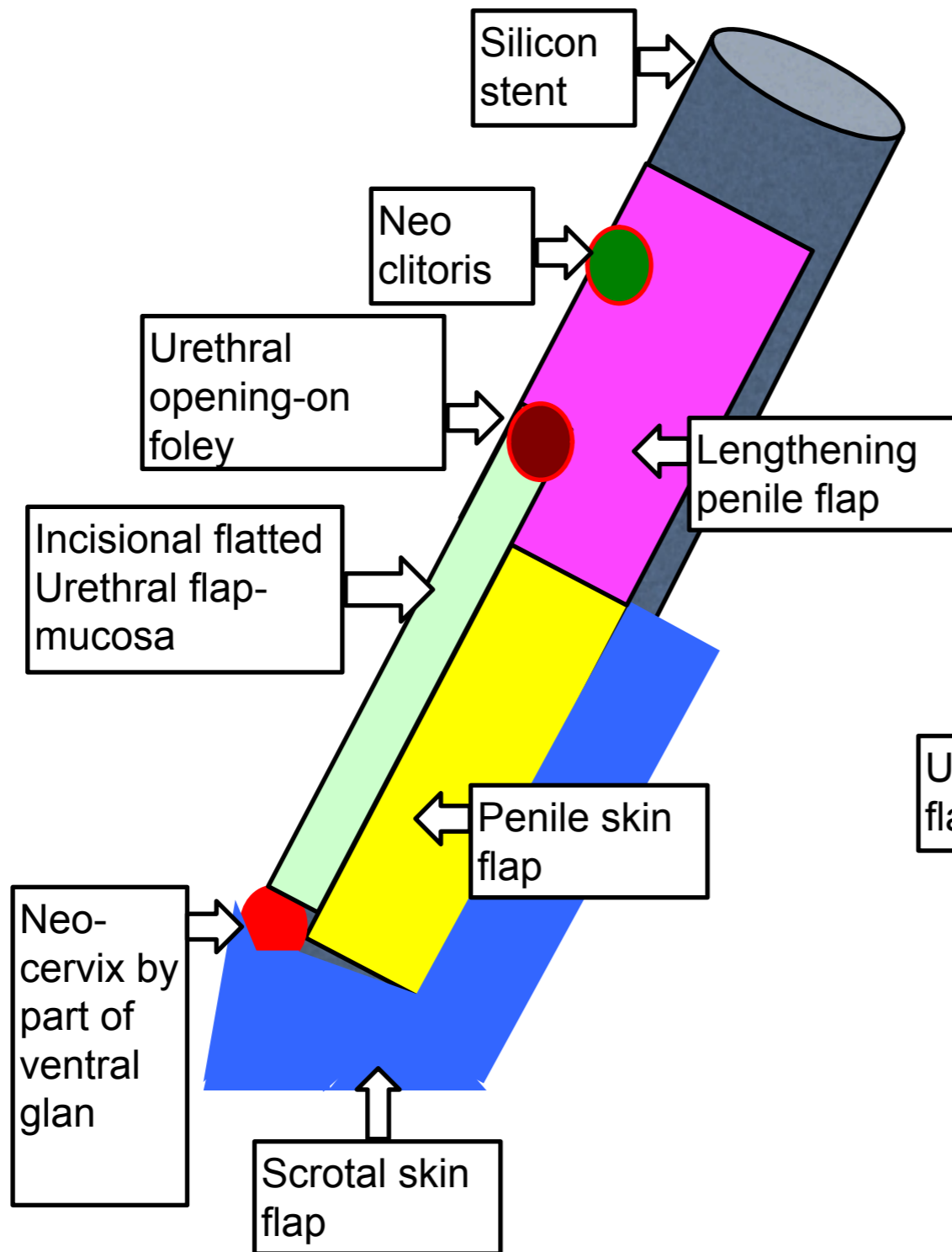


- Create neovagina between rectum and bladder by gynecologist with blunt dissection

Lengthened Penile Skin

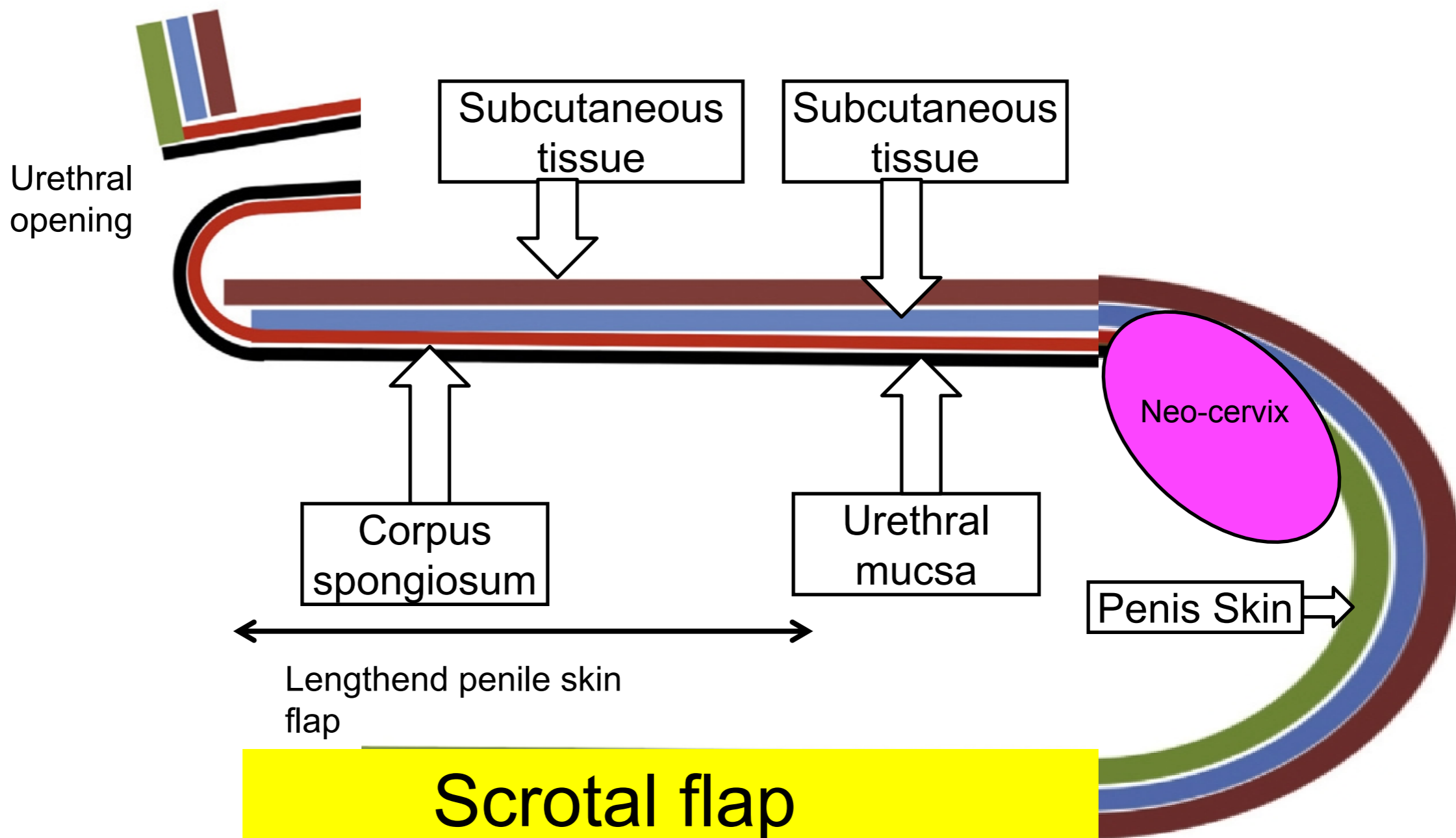


Neo-vaginoplasty





Lateral View



The Division of Plastic and Reconstructive surgery,
Department of Surgery, National Taiwan University Hospital



Result Post OP 9 months

The Division of Plastic and Reconstructive surgery,
Department of Surgery, National Taiwan University Hospital





Conclusion

- Lengthened Penile skin-urethral-scrotal flap for neovaginoplasty can provide not only satisfied moisture and sensitivity for sexual function, but create longer vaginal length to Eastern male transsexuals receiving hormone therapy with little penis.



Significance of the Findings

- Horizontal incision creating above deep fascial layer in penile skin flap can increase total flap length and the circulation of flap was still good.



The Division of Plastic and Reconstructive surgery,
Department of Surgery, National Taiwan University Hospital

台大醫院
+ NTUH
整形外科

Thank You

