

Lipoabdominoplasty in Obese Patients: Is It Safe? Has Good Results?

Alvaro L. P. C. Cansanção, MD; Alvaro J. C. Cansanção, MD; Bethania P. C. Cansanção, MD; Rafael A. Vidigal, MD.

Disclosure: The authors have no financial interest to declare in relation to the content of this article.

BACKGROUND: We currently live a wide obesity epidemic. A large percentage of these obese individuals, particularly those who have failed to lose weight with diet and exercise and do not want to undergo bariatric surgery, or those undergoing bariatric surgery failed in weight loss are potential candidates performing plastic surgery. Plastic surgery in obese is a controversial issue because of a perception that it is associated with a higher incidence of complications.¹

OBJECTIVE: The authors present data from their eight-year experience supporting lipoabdominoplasty in obese patients as a safe and effective procedure for body contouring.

METHODS AND MATERIALS: A retrospective study of consecutive 456 patients who underwent Lipoabdominoplasty by Saldanha's technique between January 2007 and December 2014.² Patients were divided into three groups and three subgroups, as showed:

- Group 1: patients with normal weight (BMI ≤ 24.9)
- Group 2: Patients with overweight (BMI $\geq 25 \leq 29.9$)
- Group 3: Obese patients (BMI ≥ 30) and the group 3 was divided in:
 - Group 3 A - Patients with class I obesity (BMI $\leq 30 \geq 34.9$)
 - Group 3 B - Patients with class II obesity (BMI $\leq 35 \geq 39.9$)
 - Group 3 C - Patients with class III obesity (BMI ≥ 40)

RESULTS: Of the 456 analyzed patients, Group 1: 82 (18.0%) in Group 2: 161 (35.3%) and in Group 3: 213 (46.7%). Seroma are higher in group 3c and Wound dehiscence in groups 3c and 3b. No other complications presented a significant difference in incidence between the groups

CONCLUSIONS: Since we follow a strict preoperative and postoperative protocol lipoabdominoplasty can be safely performed in high BMI patients.³ The incidence of complications in these patients is comparable to those found in patients with normal BMI. This technique showed excellent aesthetic results (figure 1, figure2).

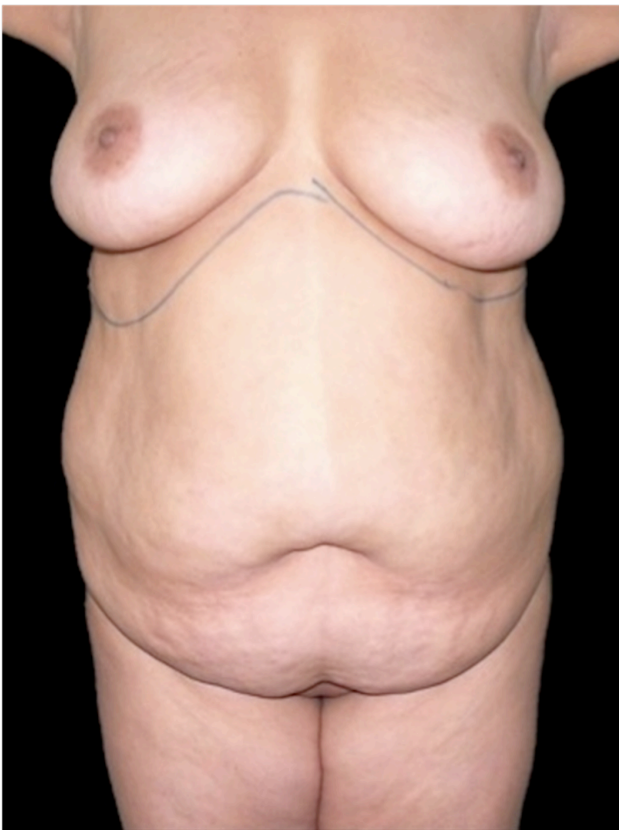


Figure 1: Patient 33 years old, 109.3 kg, class II obesity (BMI = 36.95). Subjected to Lipoabdominoplasty for removal of 7600 ml of supernatant fat (6.9% of body weight): PREOPERATIVE PHOTO

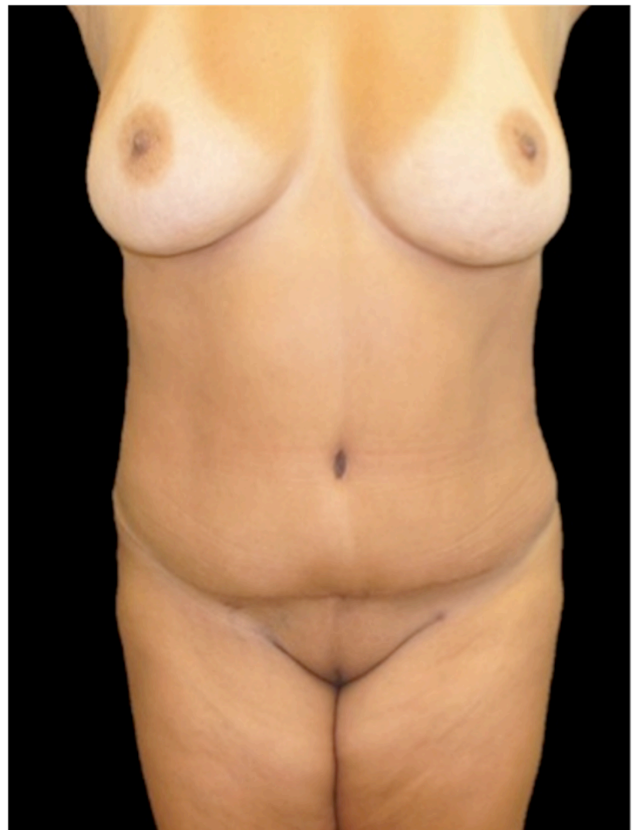

Figure 2: Patient 33 years old, 109.3 kg, class II obesity (BMI = 36.95). Subjected to Lipoabdominoplasty for removal of 7600 ml of supernatant fat (6.9% of body weight) – POSTOPERATIVE PHOTO (4th month)

REFERENCES:

1. Hurwitz D.J.; Wooten A.; Plastic surgery for the obese. *Internat. Journal of Adipose Tissue* 2007; 1(1): 5-11
2. Saldanha OR, Souza Pinto EB, Mattos Jr. WN, et al. Lipoabdominoplasty with selective and safe undermining. *Aesthetic Plast Surg.* 2003;27(4):322-7.
3. Phillip C. H.; Jennifer A. S.; Karol A. G.; et al; Evidence-Based Patient Safety Advisory: Liposuction. *Plast. Reconstr. Surg.* 124 (Suppl.): 28S, 2009.