

# Triple Rhomboid Flap for Large Skin Defects

**Larissa L. Daroda, MD; Romeu F. Daroda, MD; Carlos Eduardo G. Cruz, MD; Eduardo N. Carvalho, MD; Andressa Barra, MD**

**INTRODUCTION:** The Rhomboid flap, described by Limberg in 1946, is widely used in reconstructive procedures and is considered to be a safe and effective flap option. Since then, the flap has been modified by other authors, increasing its versatility, notably the triple flap technique, which is used for large defects. The aim of this paper is to demonstrate the applicability and results of this flap when used to cover large skin defects.

**MATERIALS AND METHODS:** A retrospective analysis of seven patients' charts was performed. These patients presented with large skin defects following oncological resections and underwent surgery between 2010 and 2014. The flaps were designed by converting skin defects into a hexagon with 120-degree angles and three of its vertices originated three flaps, then transposed into the defects, providing full coverage (figure 1).

**RESULTS:** Among the seven selected patients, in the period ranging from 2010 to 2015, four of them had basal cell carcinomas on the scalp, two had squamous cell carcinomas on the scalp and one had a metastatic colon adenocarcinoma on the abdominal wall and the minimum size of the defect was 8cm in diameter. Satisfactory result was achieved in all seven cases, with aesthetic outcome consistent with that expected. In two cases, small areas were not completely closed at first, but healed properly after 2-3 weeks (figure 2). No infection cases or alopecia areas were found in this series.

**DISCUSSION:** The triple rhomboid flap has been used since its initial report as an effective means of covering local defects. One aesthetic advantage, when compared to skin grafts, is lack of alopecia and skin tone alterations. Furthermore, the flap is designed to avoid scar contracture and to enable coverage of larger defects than it would be possible with a single rhomboid flap.

**CONCLUSION:** The triple rhomboid flap is a useful flap for large skin defects, with adequate aesthetic outcomes and few scar revisions.

## REFERENCES

1. Alvarez GS, Laitano FF, Siqueira EJ, Oliveira MP, Martins PDE. Aplicações do retalho romboide em reparações cutâneas. Rev Bras Cir Plast. 2012; 27(1):102-7.
2. Turan T, Kuran I, Ozcan H, Bas L. Geometric limit of multiple local Limberg flaps: a flap design. Plast Reconstr Surg. 1999;104(6):1675-8.
3. Jackson IT. Retalhos locais na reconstrução de cabeça e pescoço. Rio de Janeiro. Dilivros; 2002.
4. Camelo-Nunes JM, Munhoz MEP, Sartorelli Jr. AA, Tulasne JF. Reconstrução da frente, do couro cabeludo e da calvária. In: Mélega JM. Ed. Cirurgia Plástica: os princípios e a atualidade. Rio de Janeiro: Guanabara Koogan, 2011.
5. Lister GD, Gibson T. Closure of rhomboid skin defects: the flaps of Limberg and Dufourmentel. Brit J Plast Surg. 1972;25:300-14.

## FIGURE LEGEND:

**Figure 1** – Defect in the scalp due to the resection of squamous cell carcinoma.

**Figure 2** – Triple rhomboid for a defect in the scalp.

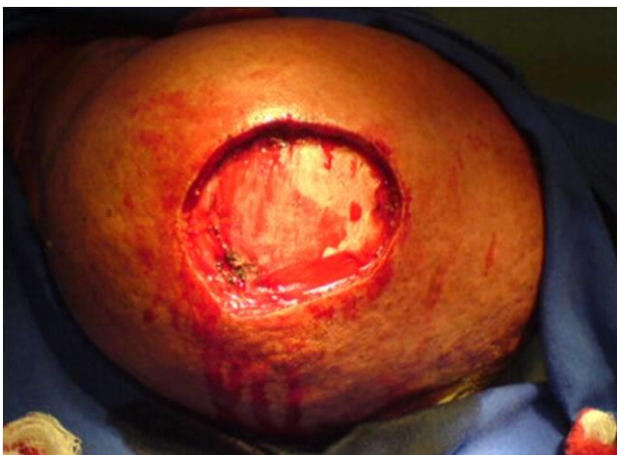

Figure 1

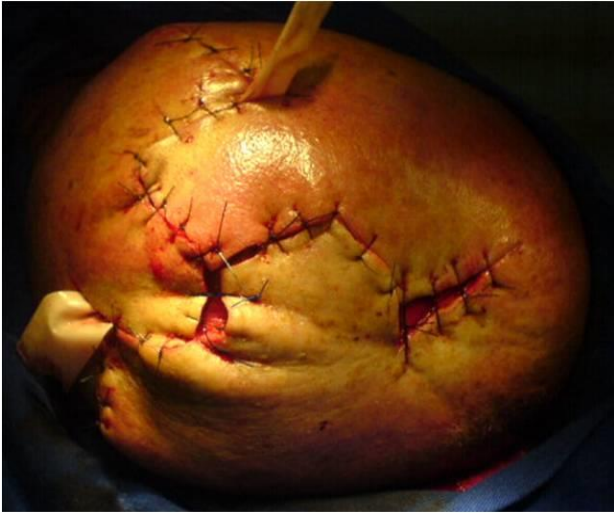


Figure 2