

Scar Reducing Effect of the Silicone Gel Sheet with Verapamil in a Rabbit Model of Hypertrophic Scar

Eun Young Rha, MD; Jong Won Rhie, MD, PhD

Disclosure/Financial Support: None of the authors has a financial interest in any of the products, devices, or drugs mentioned in this manuscript.

INTRODUCTION: The CCB verapamil is clinically effective in the treatment of HTSs when injected intralesionally.^{1,2} We developed a novel treatment based on the topical application of a silicone gel sheet (SGS) containing verapamil microparticles. The ability of these SGSs to inhibit hypertrophic scar (HTS) formation in a rabbit ear wound model was examined.

MATERIALS AND METHODS: Ten New Zealand White (NZW) rabbits with a total of 80 wounds in both ears were used in this study. The rabbits were divided into five groups (control, SGS, and SGS+0.25, 2.5, and 25 mg verapamil/g). Histopathologic findings were quantified based on the scar elevation index (SEI) and fibroblast and capillary counts.

RESULTS: The mean SEI, fibroblast counts, and capillary counts differed significantly among the five groups ($P < 0.05$). The median SEI was significantly lower in the SGS+2.5 mg verapamil/g group (Figure 1) than in the SGS group (Figure 2) (1.2 vs. 2.2). The median number of fibroblasts was significantly lower in the SGS+0.25 mg verapamil/g group than in the SGS group (172.5 vs. 243). The median number of capillary lumina was significantly higher in the untreated control group (29.5) whereas there was no significant difference between the SGS group and the SGS+0.25, SGS+2.5, and SGS+25 mg verapamil/g groups (28.5, 18, 20, and 18, respectively).

CONCLUSION: Topical application of SGS with verapamil microparticles may be a novel, effective treatment method for HTS but its safety and efficacy in humans must be tested in clinical trials.

REFERENCES:

1. Doong H, Dissanayake S, Gowrishankar TR, LaBarbera MC, Lee RC. The 1996 Lindberg Award. Calcium antagonists alter cell shape and induce procollagenase synthesis in keloid and normal human dermal fibroblasts. *J Burn Care Rehabil.* 1996; 17: 497-514
2. Lee RC, Doong H, Jellema AF. The response of burn scars to intralesional verapamil. Report of five cases. *Arch Surg.* 1994; 129: 107-11

FIGURE LEGEND:

Figure 1. Histopathologic findings of the SGS+0.25 mg verapamil/g group. It has the hypertrophic scar. But scar hypertrophy, fibroblast proliferation and dense connective tissue are less prevalent in this group as compared with the control group and the SGS group (arrow).

Figure 2. Histopathologic findings of the SGS group. There are fibroblast proliferation with dense connective tissue, rich capillary lumina and hypertrophic scar (arrow).

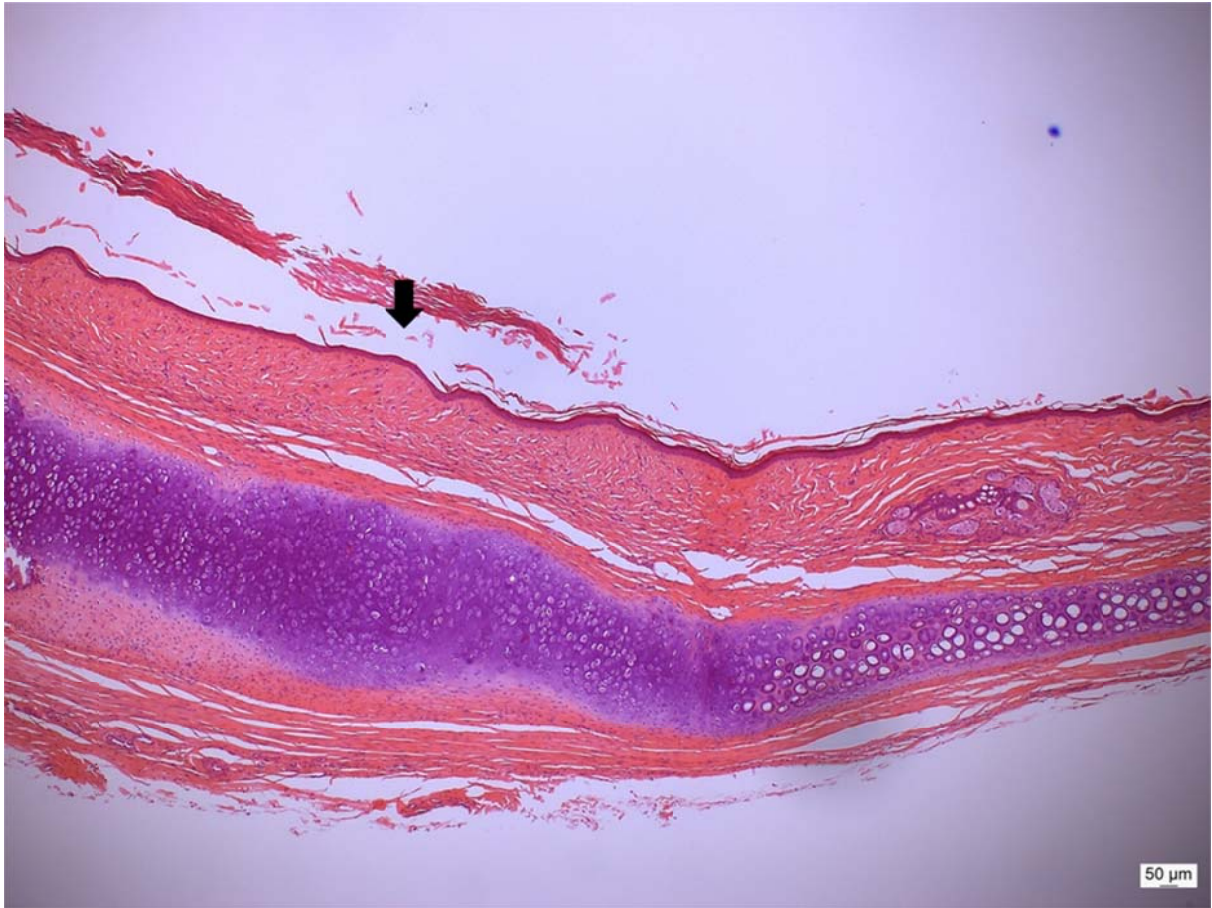


Figure 1

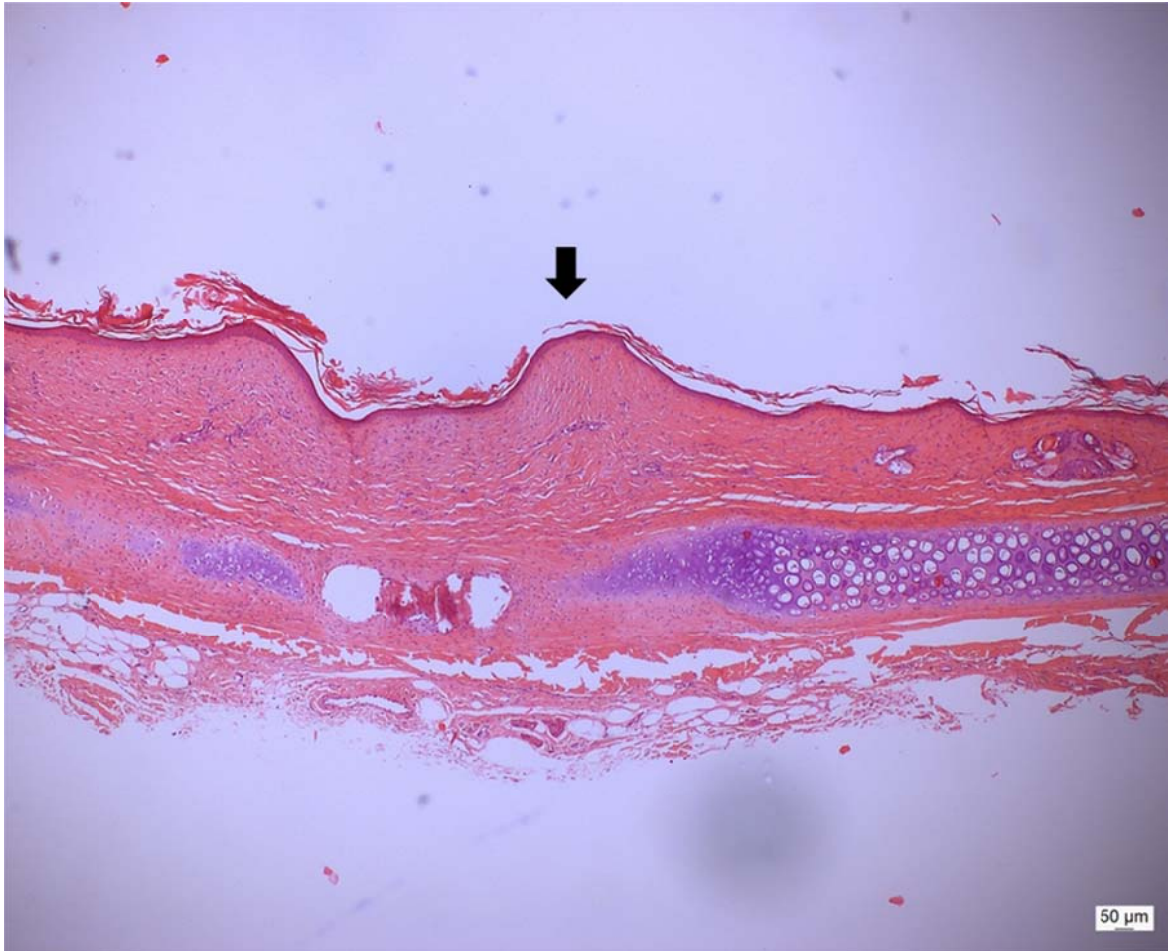


Figure 2