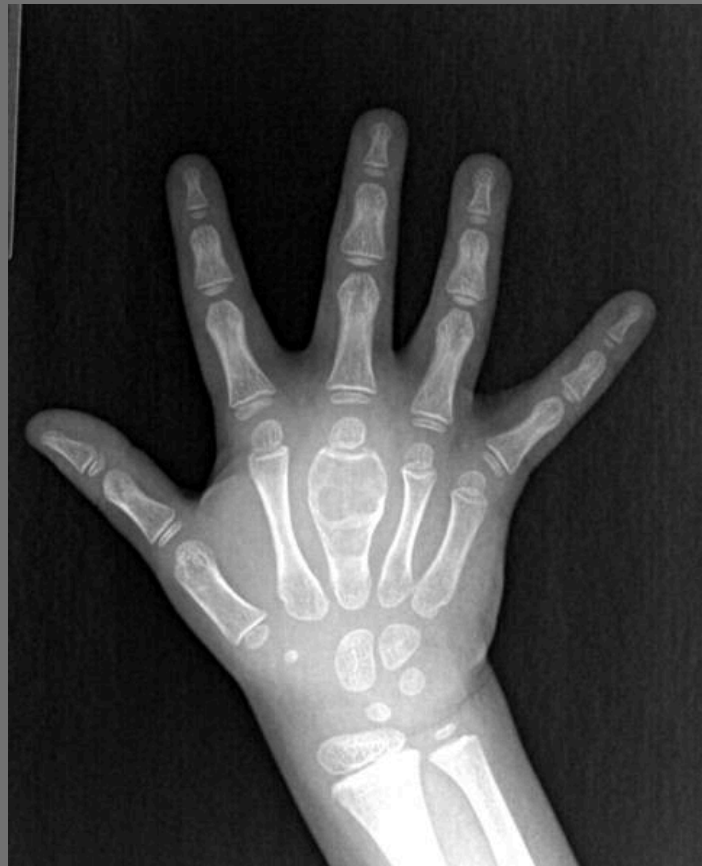

A Rare Case: Aneurysmal Bone Cyst in the Metacarpal of a Child

Catherine R. Murphree BS, Michael T. Friel MD FAAP

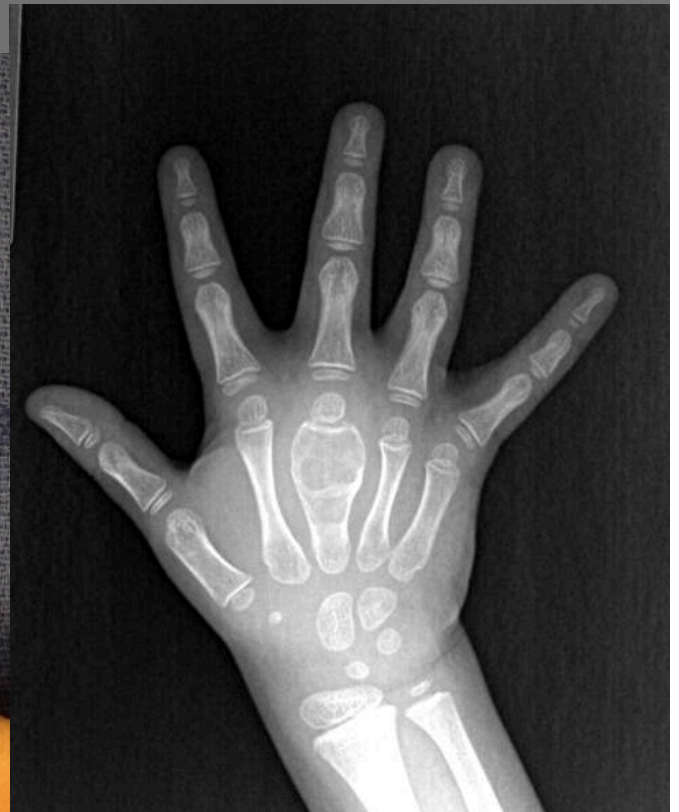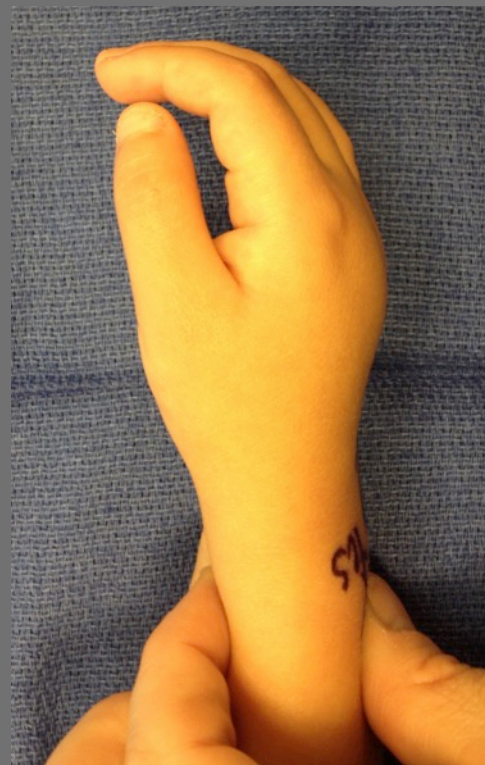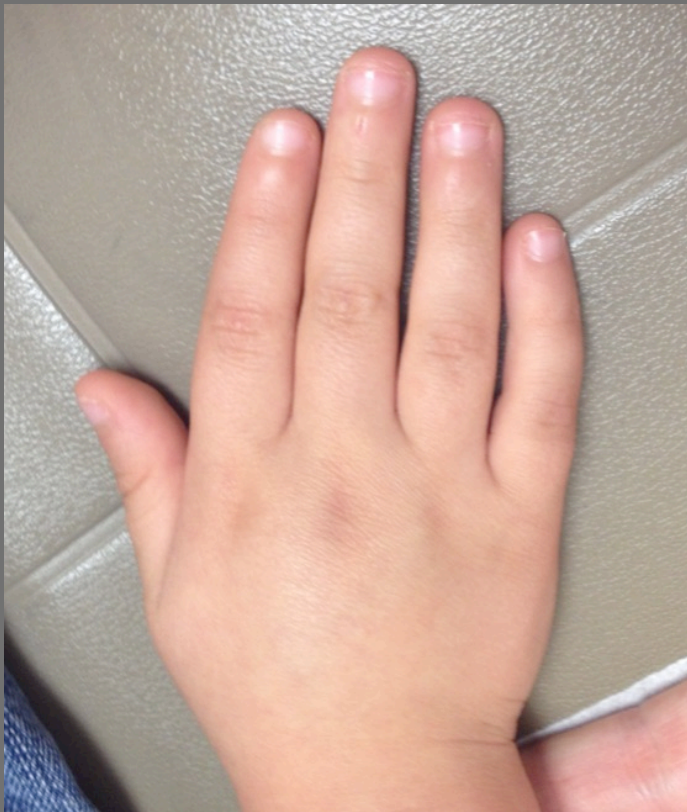University of Mississippi Medical Center, Division of Plastic Surgery



We have no Financial Disclosures to Report

Patient Presentation

5 year old boy with progressive enlargement with right hand pain over a 6 month period

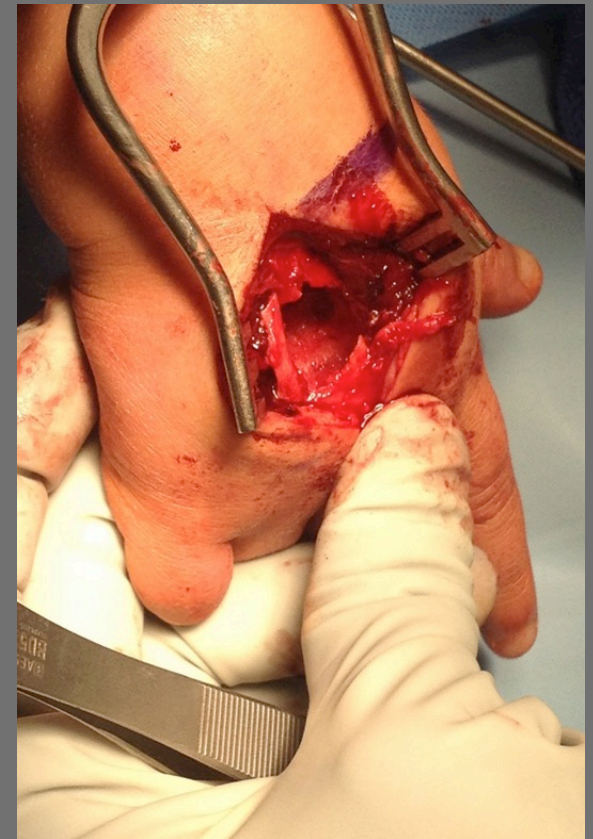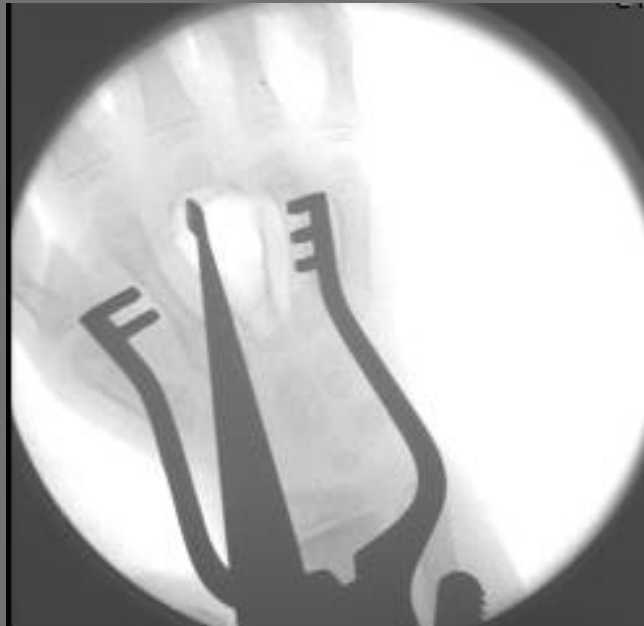

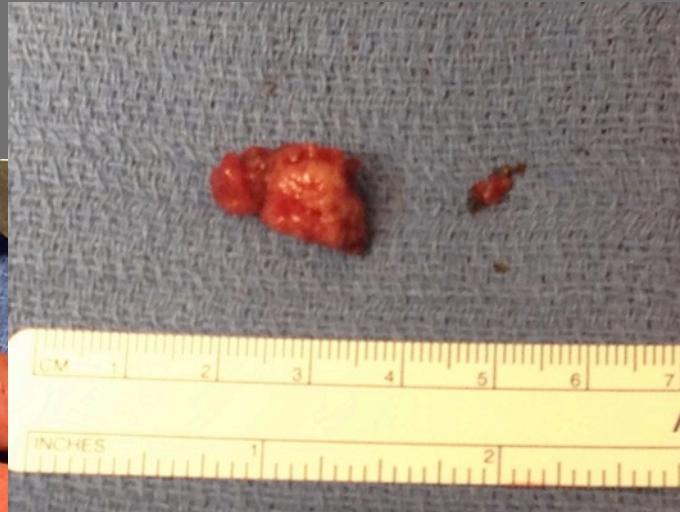
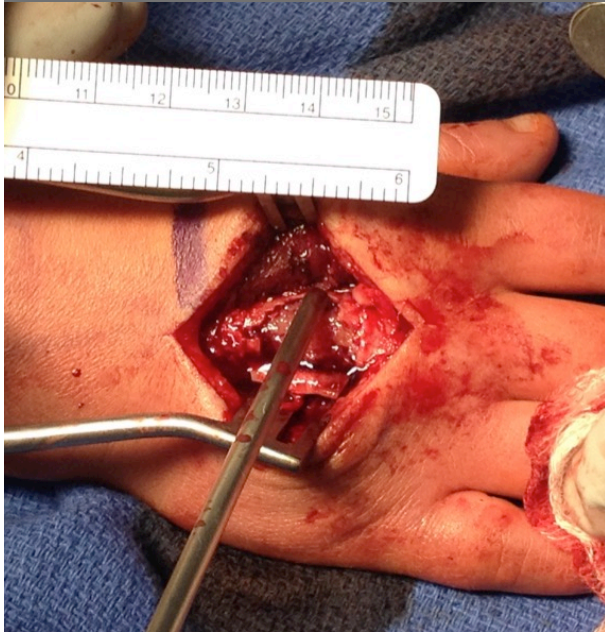Aneurysmal Bone Cysts

- Rare, rapidly growing, destructive benign tumor
- No evidence based protocol for treatment and only a handful of case reports on the management

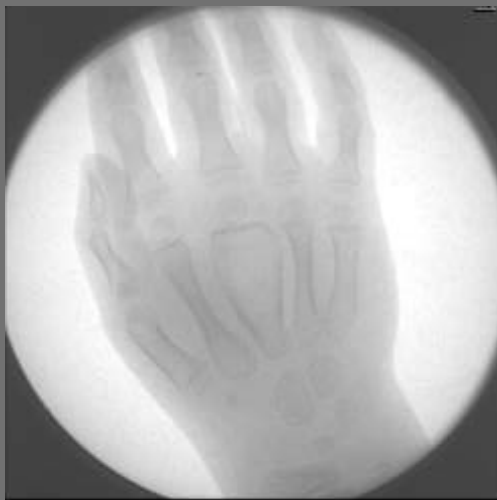- In this case, the cyst occupies 90% of the 3rd metacarpal
- Goal was to remove the cyst, reconstruct the metacarpal, while preserving length, growth potential, and function
- No recurrence at two years post-op

Curettage of Cyst and Iliac Crest Bone Grafting

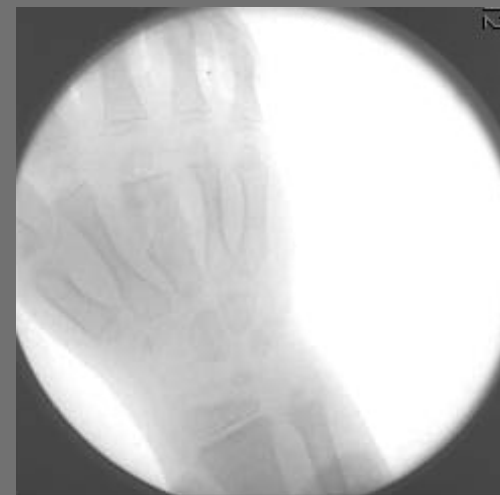

Radiographic Progression

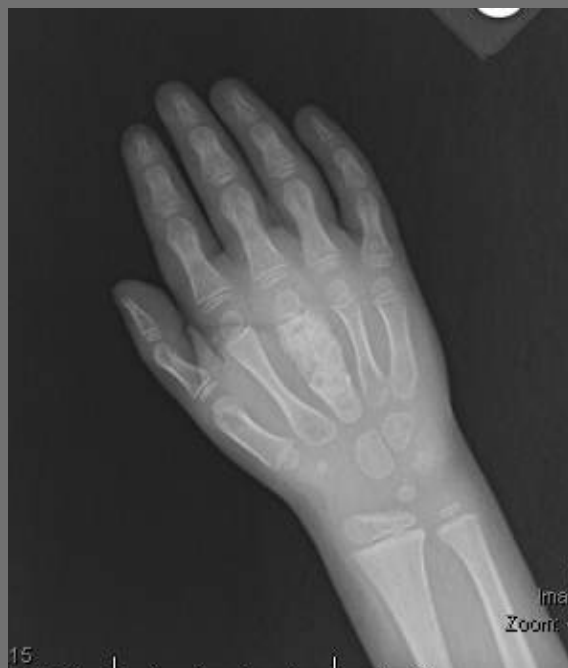Preop



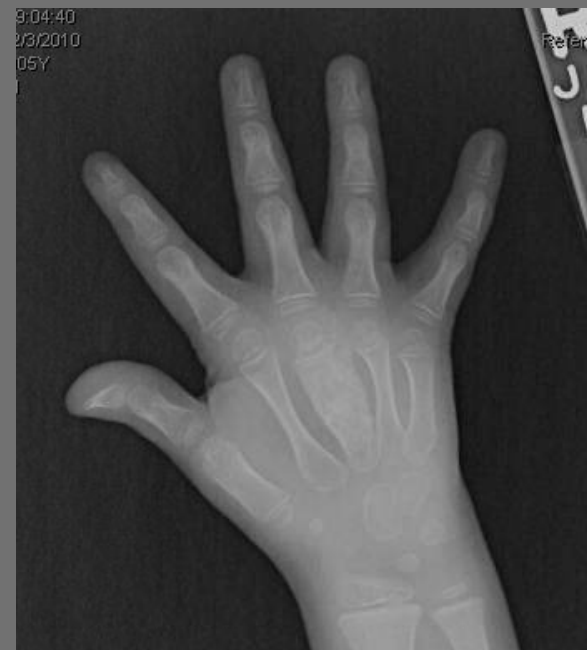PostOp



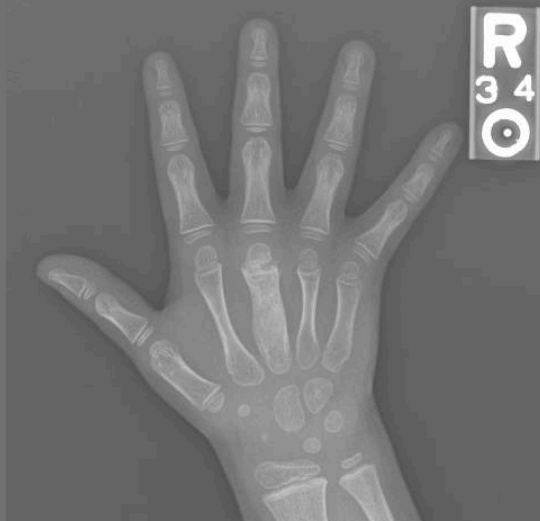1 week
postOp



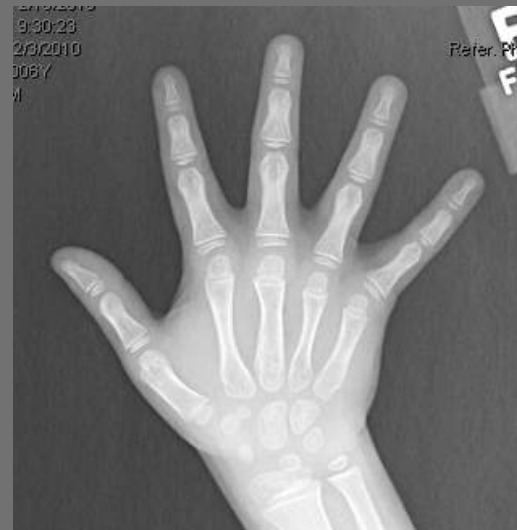3 weeks
postOp



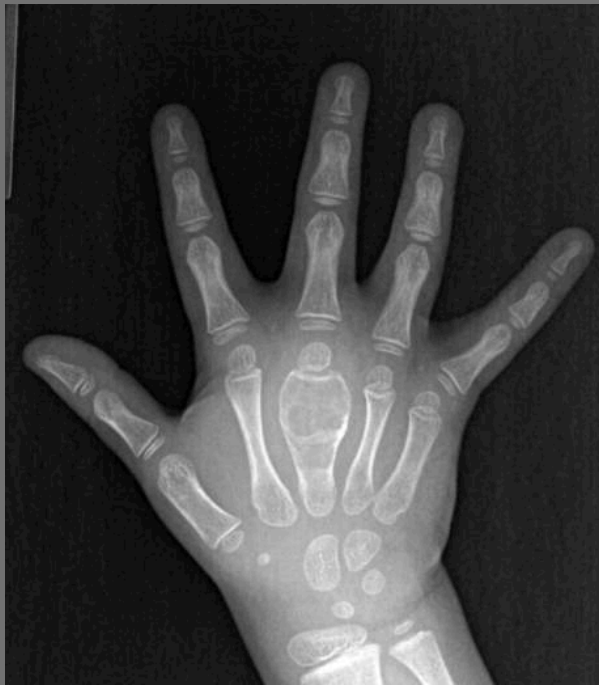2 months post-op



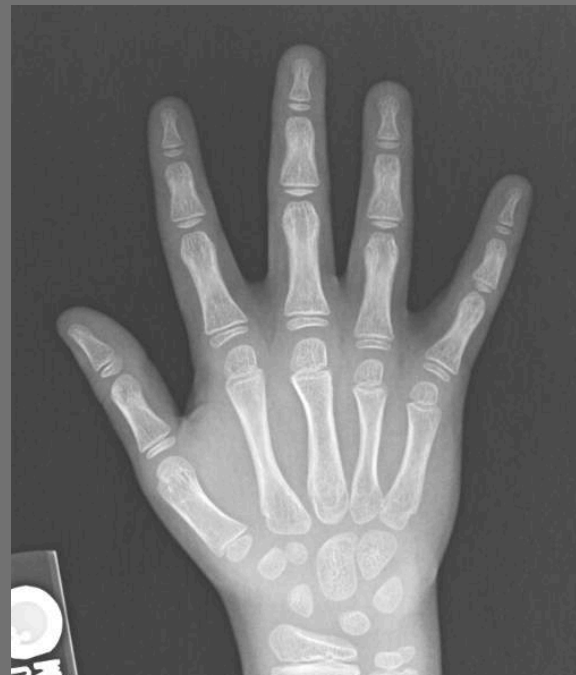6 months post-op



Preop



2 years post-op



Aneurysmal Bone Cysts in the hand of a child is incredibly rare.

This case report adds to the paucity of material on the topic

Continued annual surveillance for 5 years is recommended to monitor for recurrence

In this case, curettage and cancellous bone grafting was effective

References

1. Al-Qattan, M. M. (2014). Bipolar Electric Cauterization as Adjuvant Treatment After Curettage of Aneurysmal Bone Cysts of the Hand. *Ann Plast Surg*, 72(1), 38–40.
2. Borrelli, J., & McCormack, R. R. (1994). Aneurysmal bone cyst involving the long finger metacarpal in a child: a case report. *Journal of Hand Surgery*, 19(5), 800–802.
3. Fuhs SE, Herndon JH. (1979). Aneurysmal bone cyst involving the hand: A review and report of two cases. *Journal of Hand Surgery*, 4(2), 152–159.
4. Jafari, D., Jamshidi, K., Najdmazhar, F., Shariatzade, H., & Liaghat, O. (2011). Expansile aneurysmal bone cyst in the tubular bones of the hand treated with en bloc excision and autograft reconstruction: a report of 12 cases. *Journal of Hand Surgery (European Volume)*, 36(8), 648–655.
5. Kieseritzky, J. V., & Widenfalk, B. (2012). Treatment of a large aneurysmal bone cyst in a 15-year-old boy using a corticospongiol bone graft and a 12-year follow-up after operation. *Journal of Plastic Surgery and Hand Surgery*, 46(2), 132–136.
6. Kotwal, P. P., Jayaswal, A., Singh, M. K., & Dave, P. K. (1988). Aneurysmal bone cyst in the metacarpal of a child: a case report. *Journal of Hand Surgery (Edinburgh, Scotland)*, 13(4), 479–480.
7. Mascard, E., Gomez-Brouchet, A., & Lambot, K. (2015). Bone cysts: Unicameral and aneurysmal bone cyst. *Orthopaedics & Traumatology: Surgery & Research*, 101(1)
8. Crowe MW, Houdek MT, Moran SL, Kakar S (2015). Aneurysmal Bone Cysts of the Hand, Wrist, and Forearm. *Journal of Hand Surgery*, 40(10), 2052–2057.
9. Ozyurek, S., Rodop, O., Kose, O., Cilli, F., & Mahirogullari, M. (2009). Aneurysmal Bone Cyst of the Fifth Metacarpal. *Orthopedics*, 32(8), 606–609.
10. Kapila R, Singh S. Primary Epiphyseal Aneurysmal Bone Cyst Of Distal Ulna. (2016). *Journal of Orthopedic Case Reports*. Oct 5(4) 85-87
11. Athanasian EA, McCormack RR. Recurrent Aneurysmal Bone Cyst of the Proximal Phalanx Treated With Cryosurgery: A Case Report. *Jornal of Hand Surgery* (1999). 1–8.
12. Ropars, M., Kaila, R., Briggs, T., & Cannon, S. (2007). Kystes anévrismaux des phalanges et des métacarpiens. À propos de six cas et revue de la littérature. *Chirurgie De La Main*, 26(4-5), 214–217. doi:10.1016/j.main.2007.08.002
13. Song, K. S., Lee, S. W., Bae, K. C., & Sohn, E. S. (2015). Aneurysmal bone cyst involving the metacarpal bone in a child. *American Journal of Orthopedics* 44(3), E68–70.
14. Wang EH, Marfori ML, Serrano, MV, & Rubio DA (2014). Is Curettage and High-speed Burring Sufficient Treatment for Aneurysmal Bone Cysts? *Clinical Orthopaedics and Related Research*, 472(11), 3483–3488.